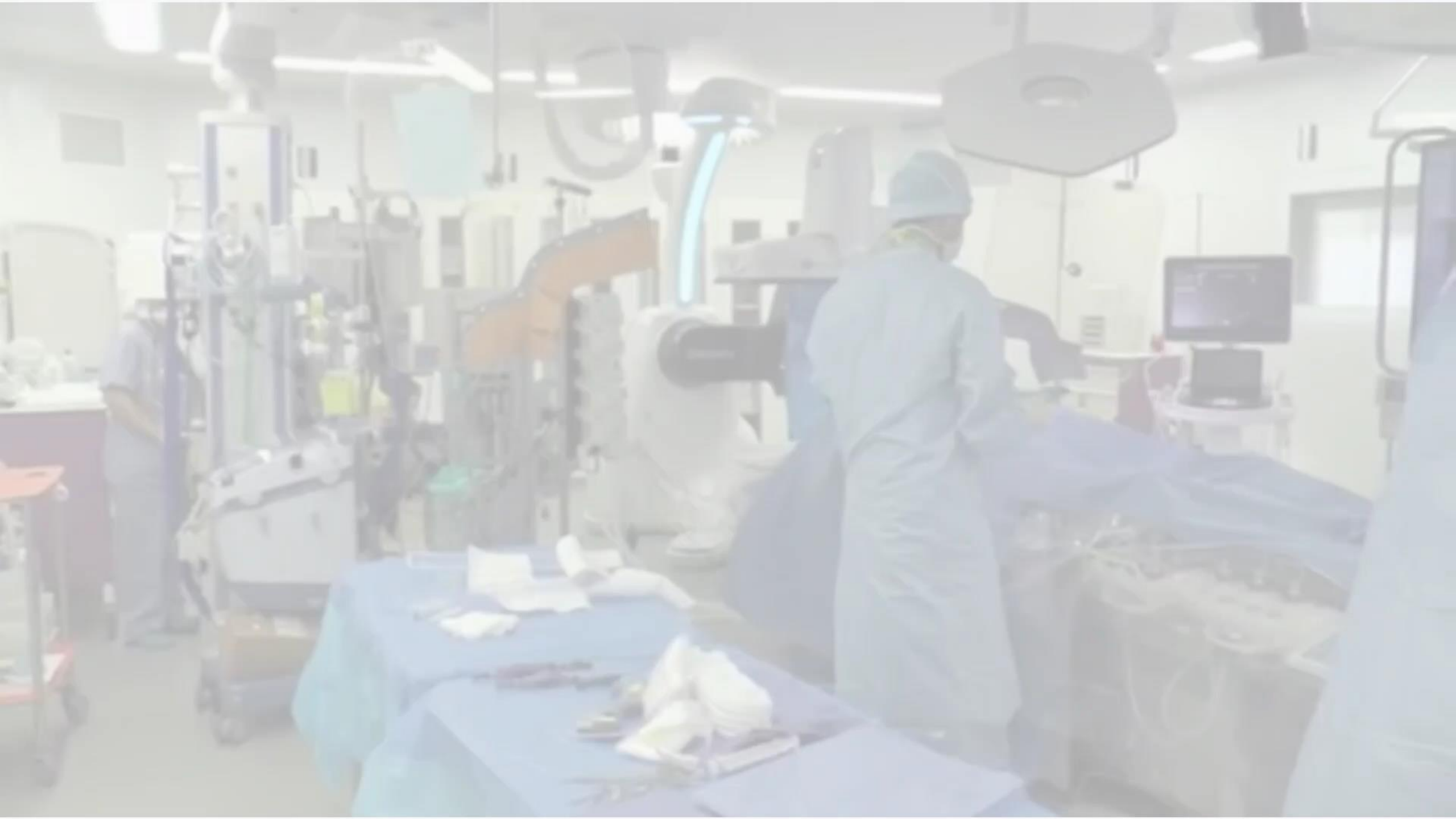






69 years old, hypertension

- Stanford type A dissection 6 years ago
Dacron straight tube in ascending aorta
- Acute bilateral lower limb ischemia
- Left kidney malperfusion
TEVAR, infra-renal, left renal and bi-iliac stenting



SIX YEARS

LATER...

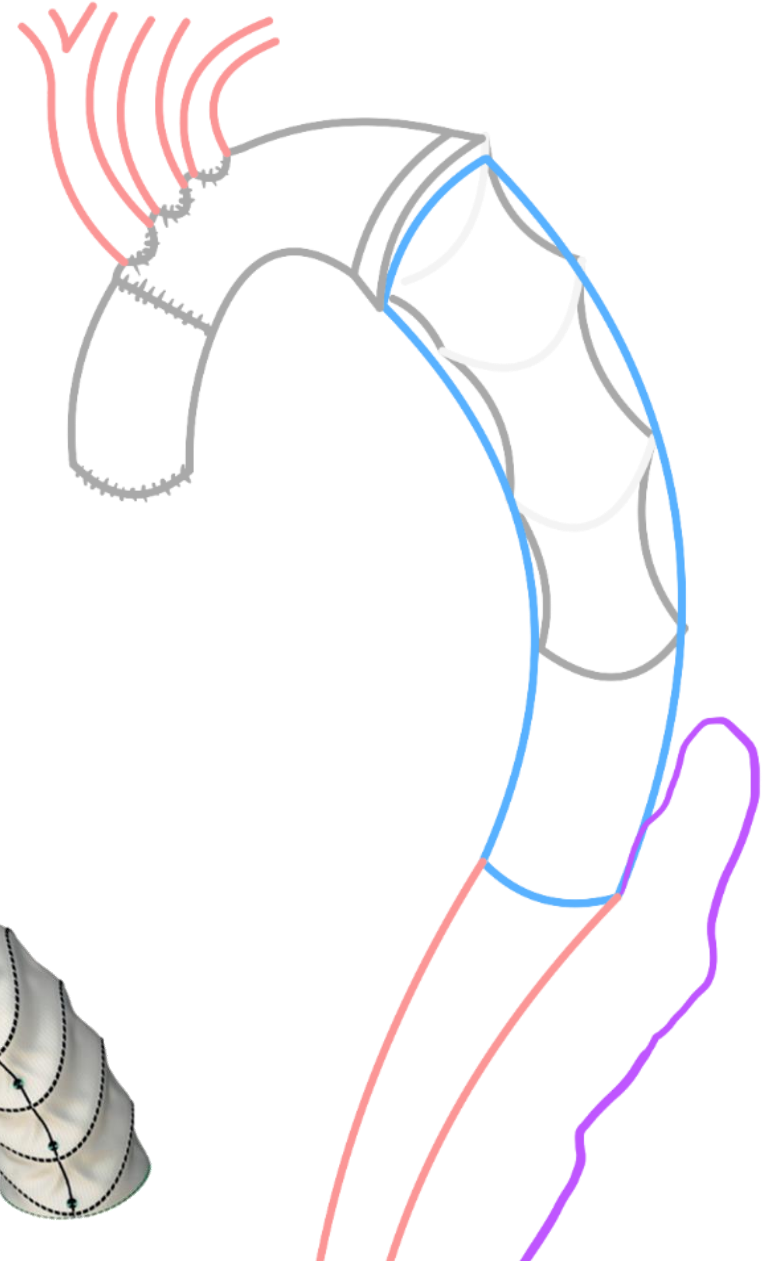
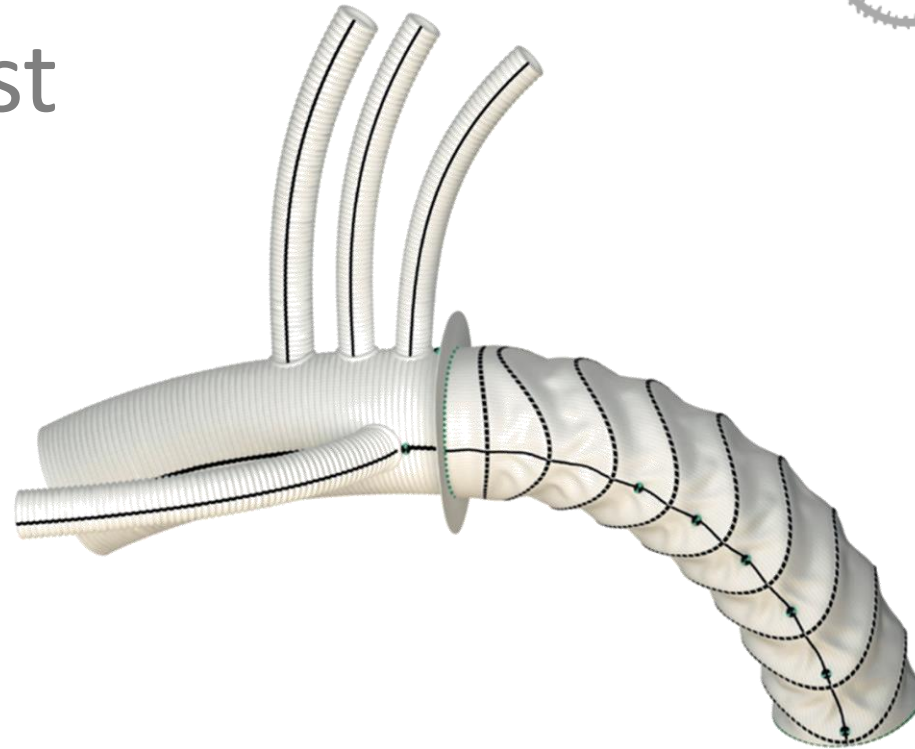


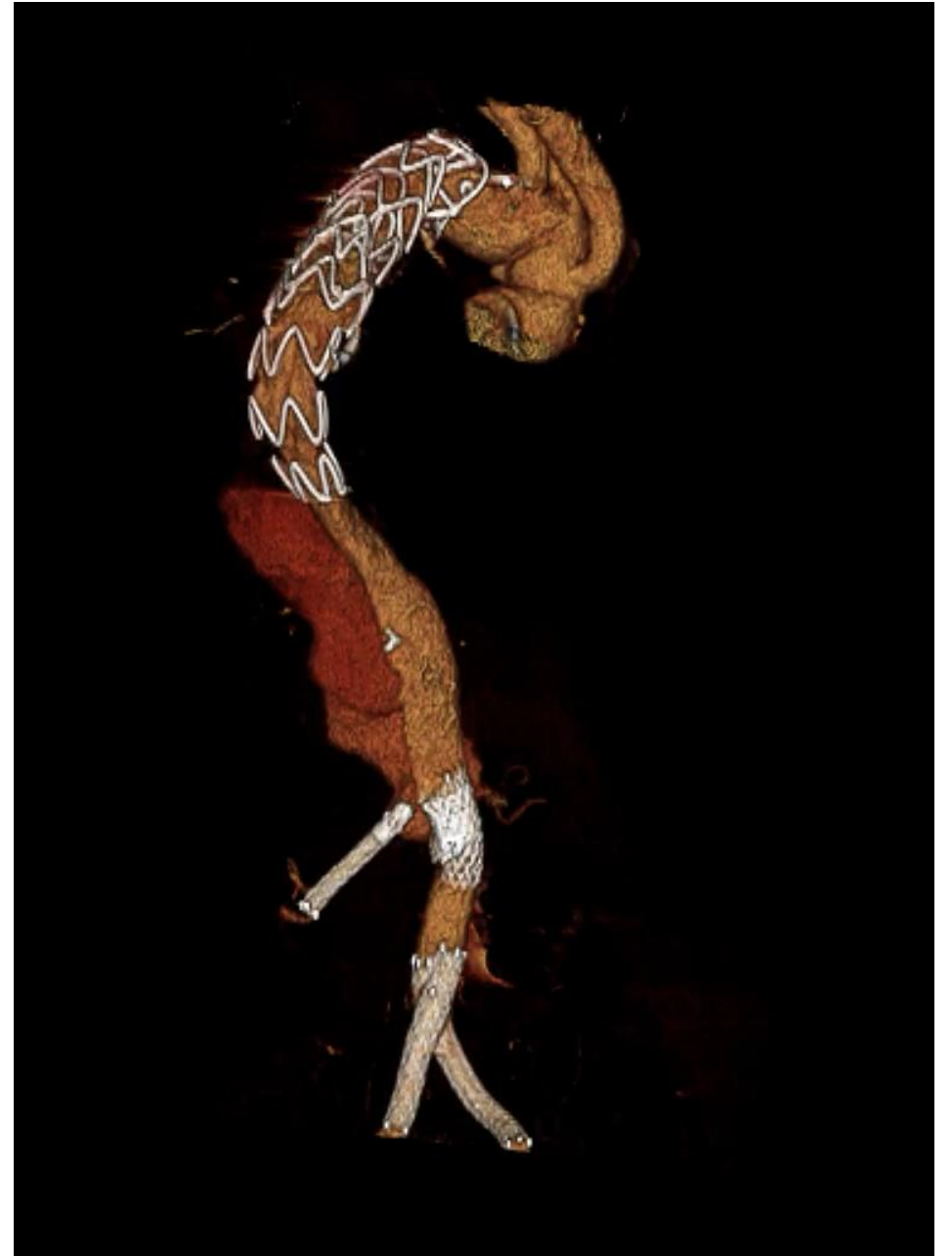
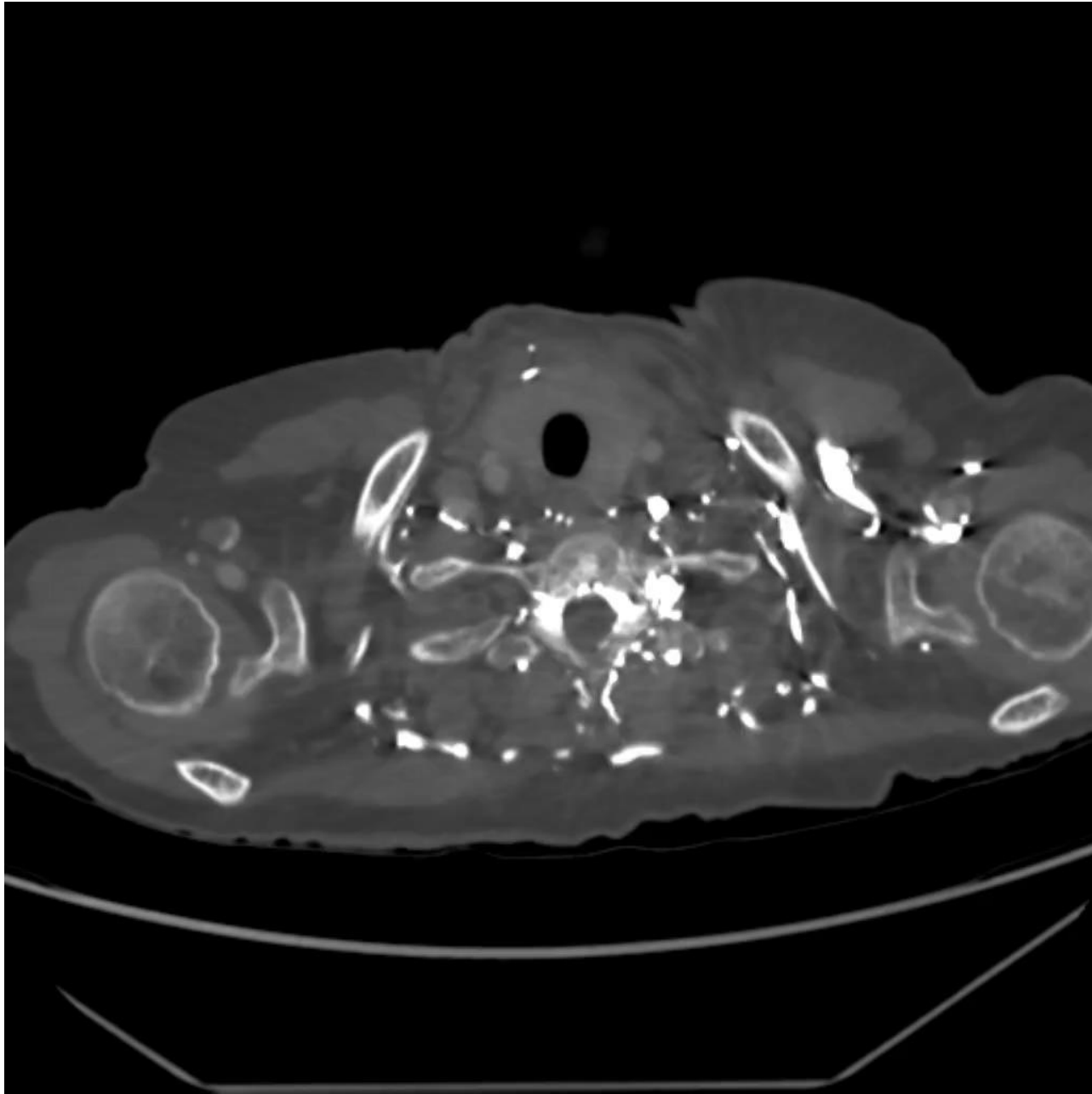
Frozen elephant trunk

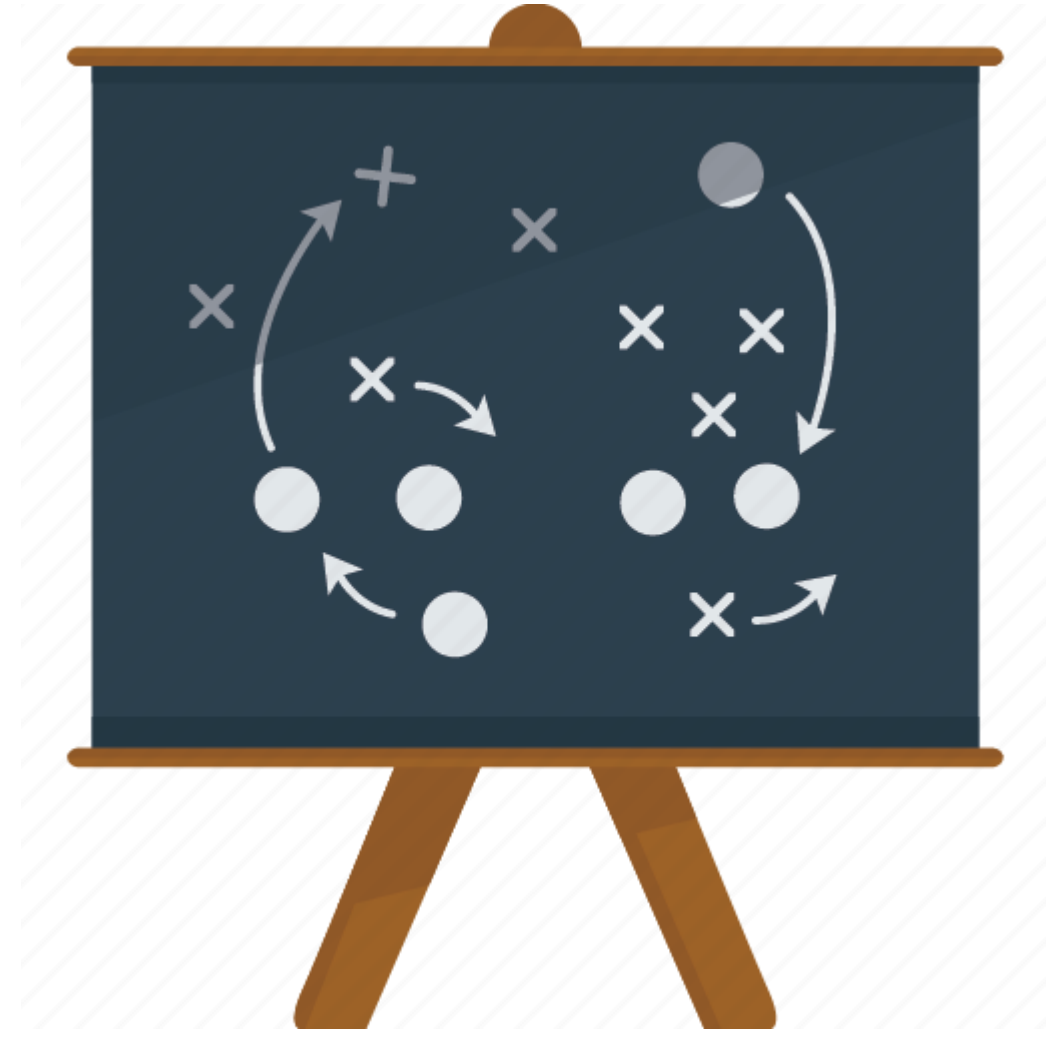
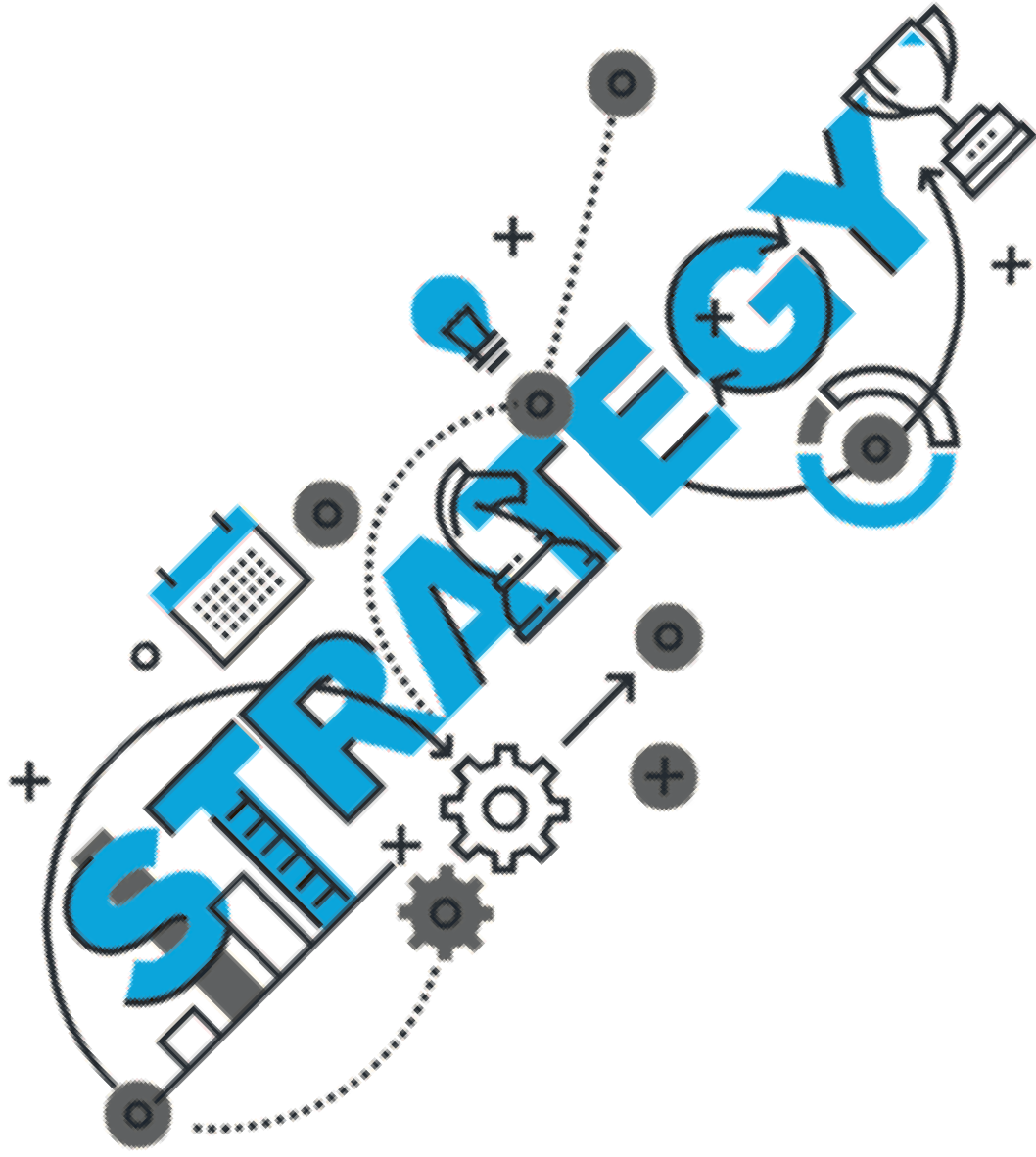Re-do sternotomy

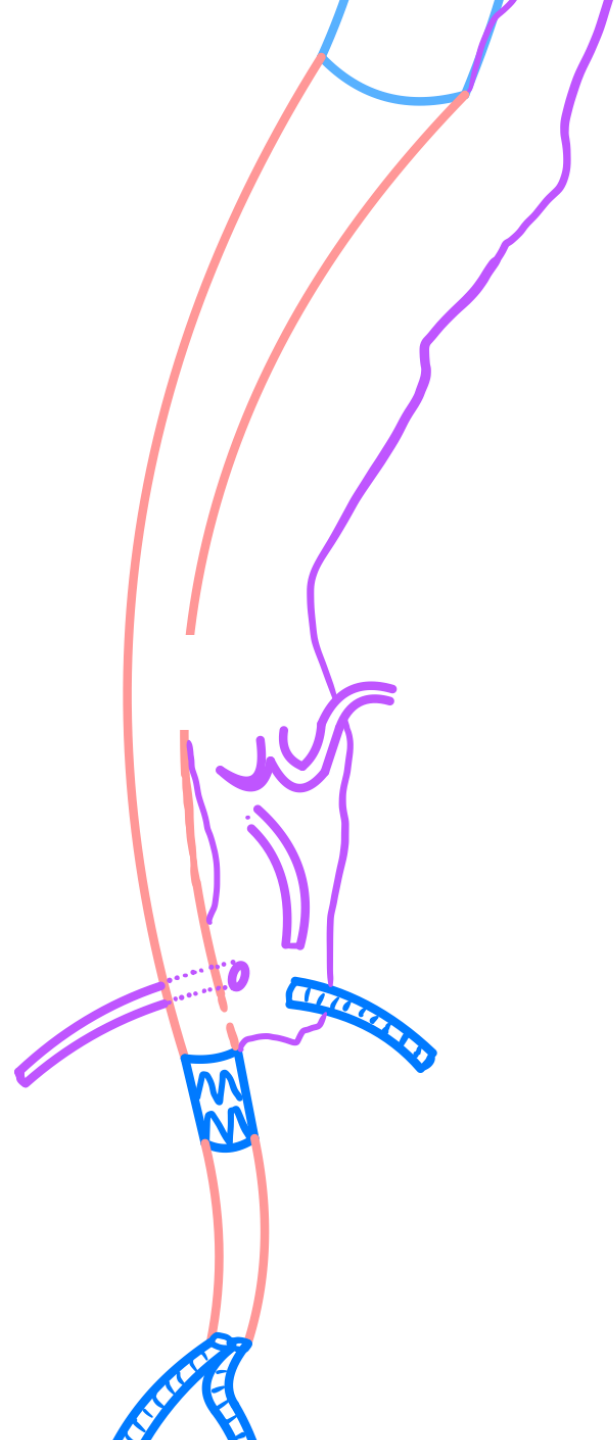
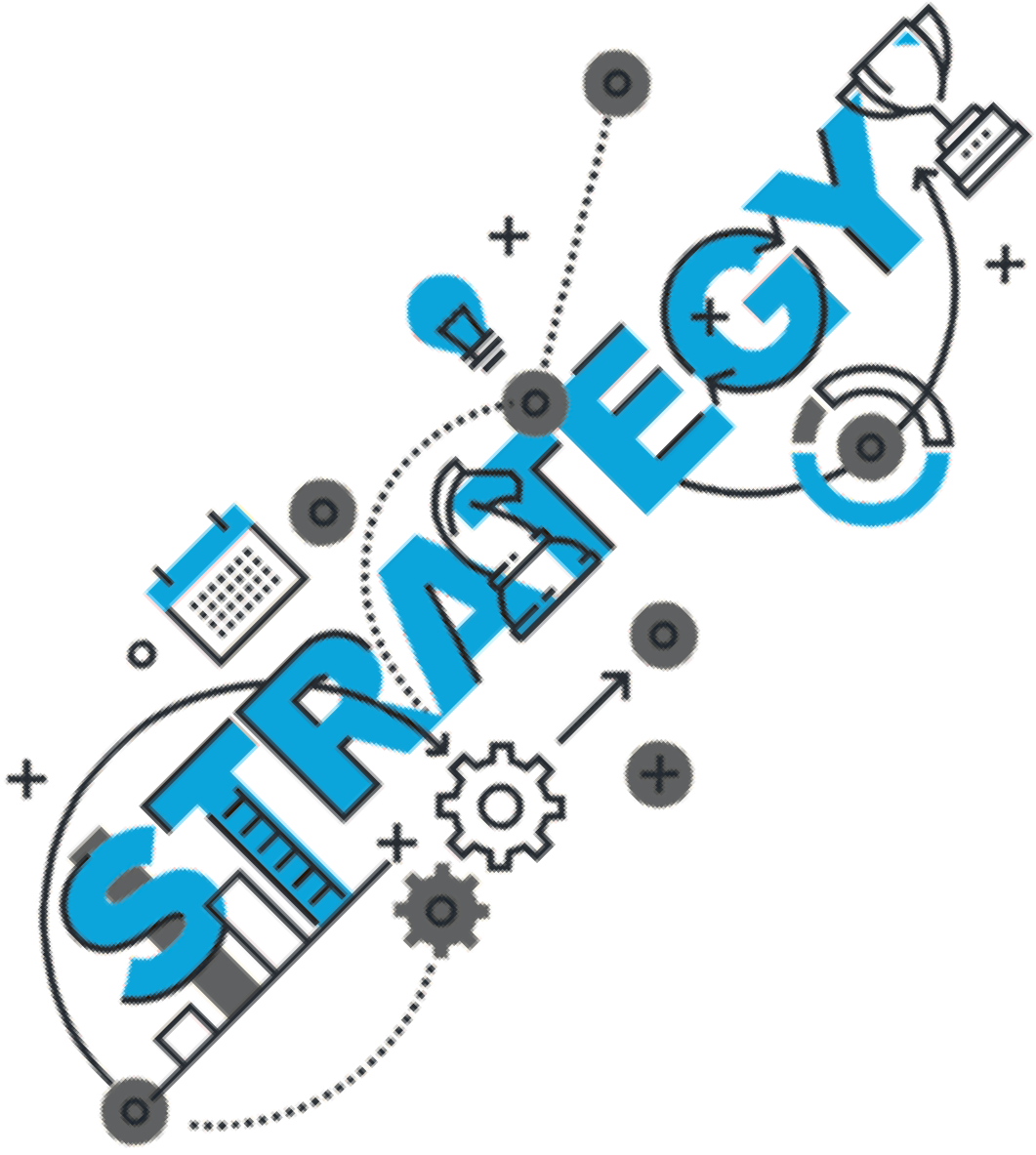Hypothermic circulatory

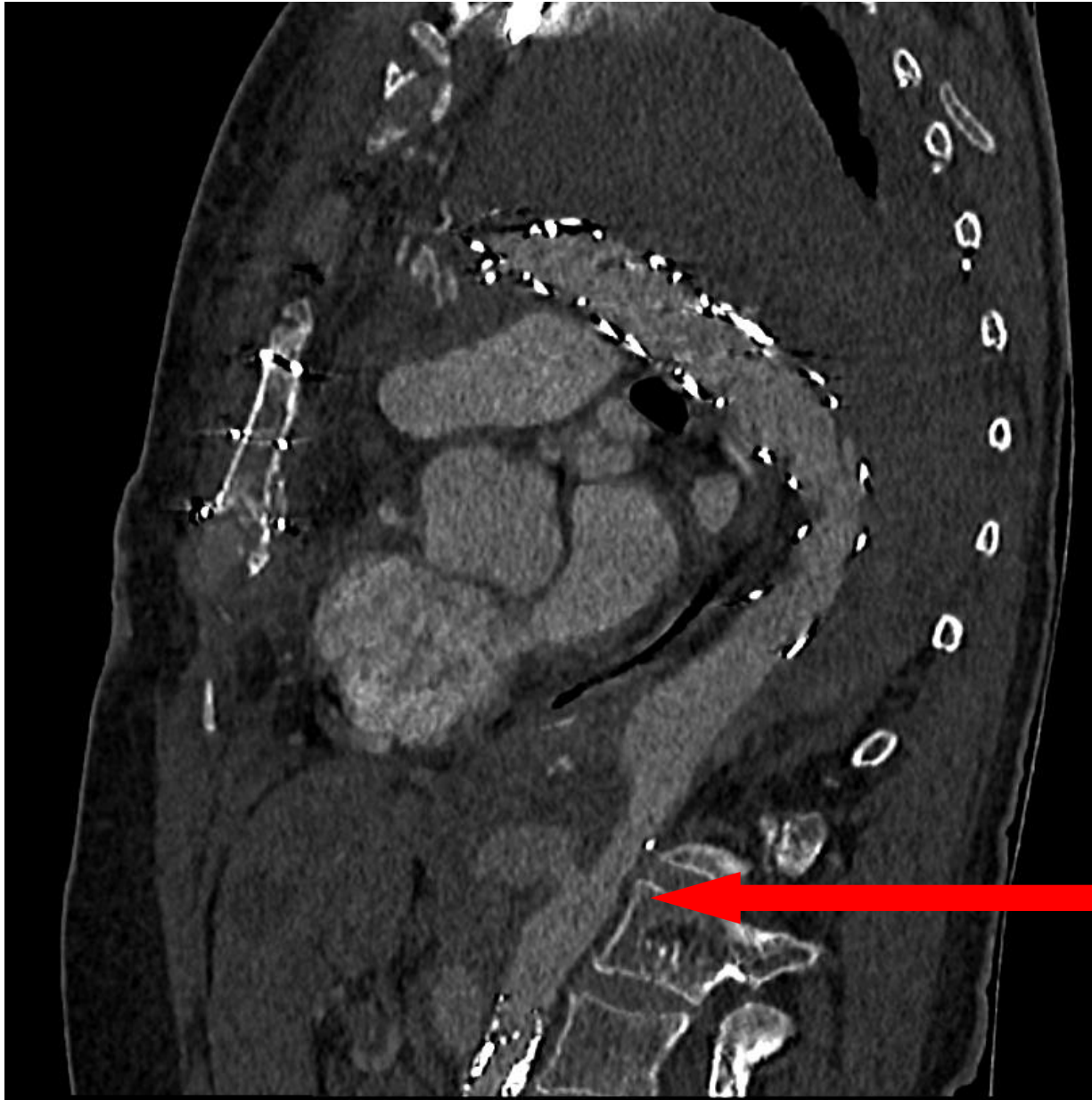arrest





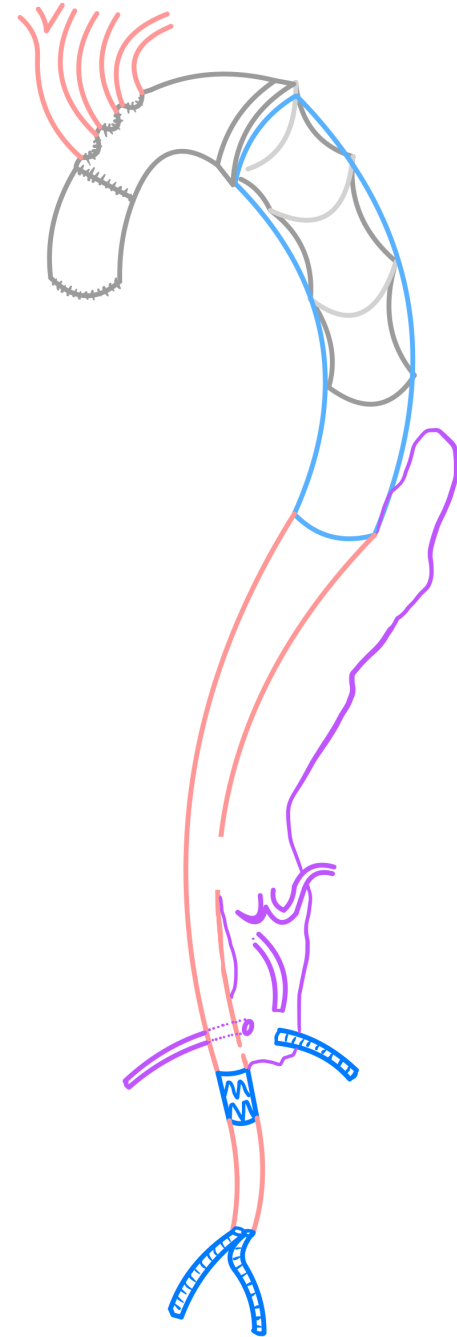






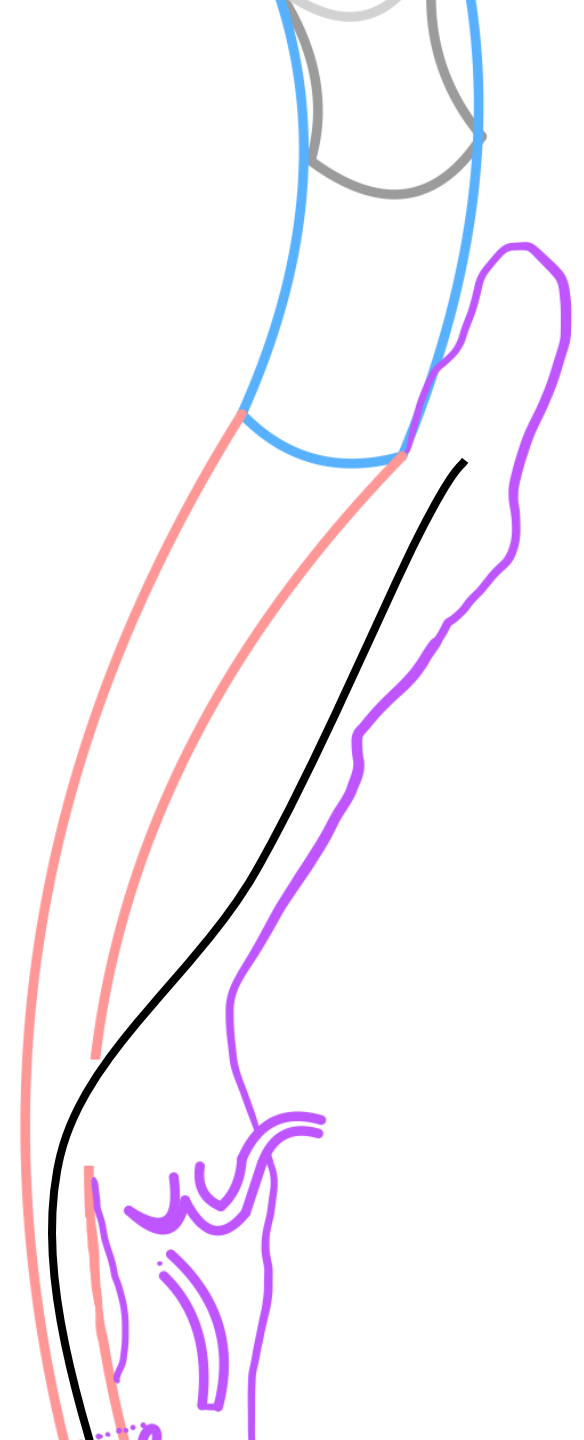
True – false lumen
communication

Positioning the t-Branch



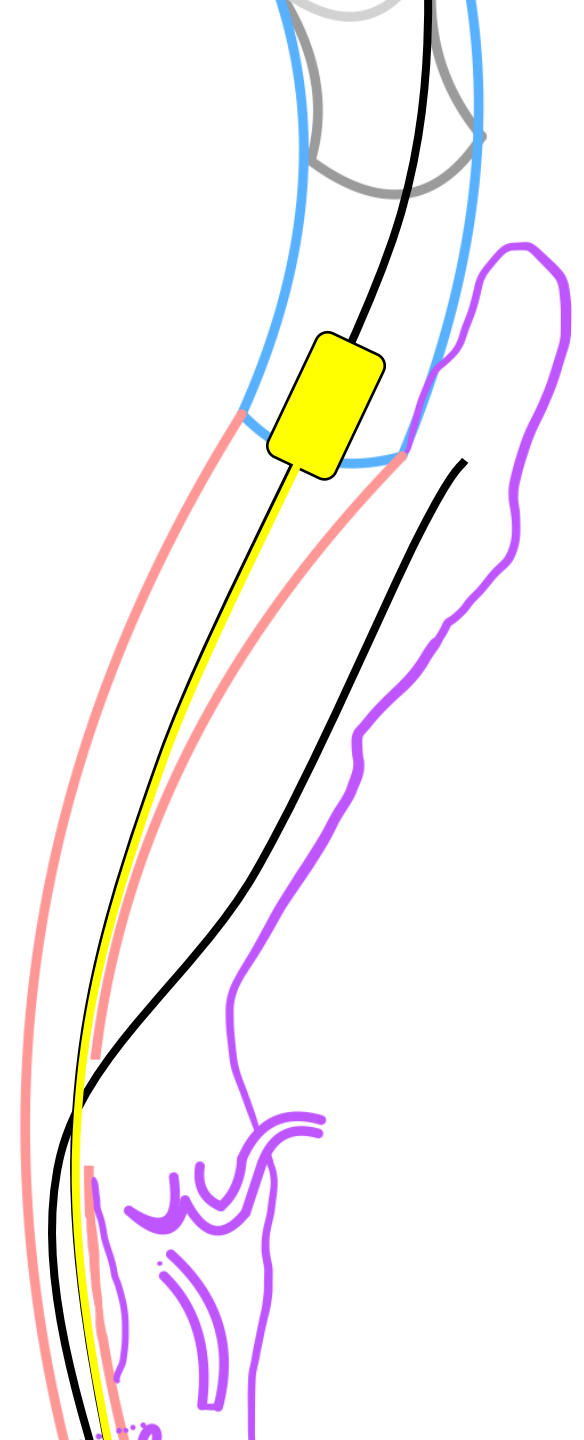
Positioning the t-Branch

- Cannulating the false lumen
- Creating a re-entry tear
- Cannulate the TEVAR
- Deploy the t-Branch



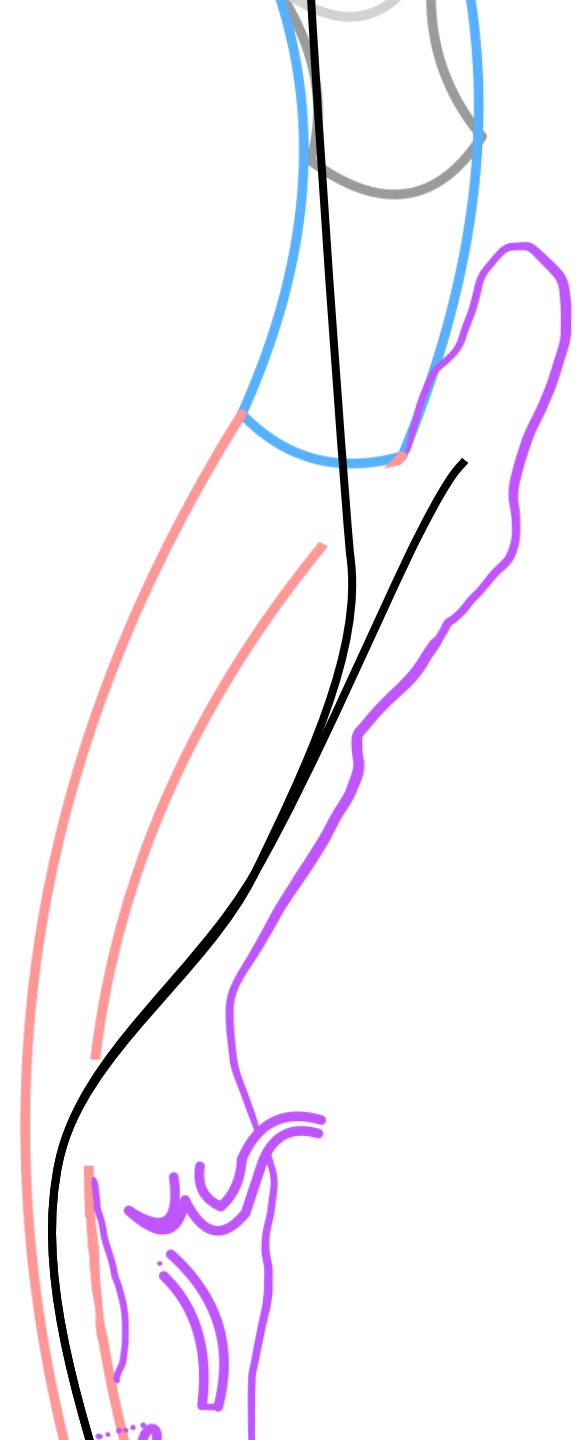
Positioning the t-Branch

- Cannulating the false lumen
- Creating a re-entry tear
- Cannulate the TEVAR
- Deploy the t-Branch



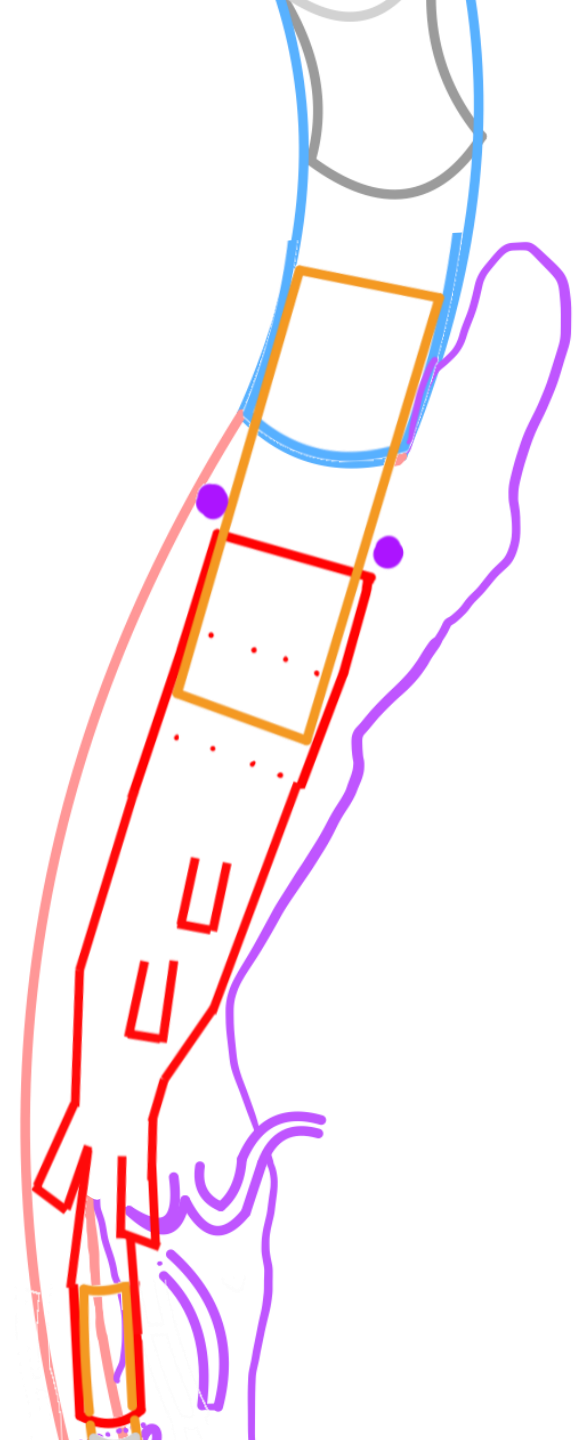
Positioning the t-Branch

- Cannulating the false lumen
- Creating a re-entry tear
- Cannulate the TEVAR
- Deploy the t-Branch



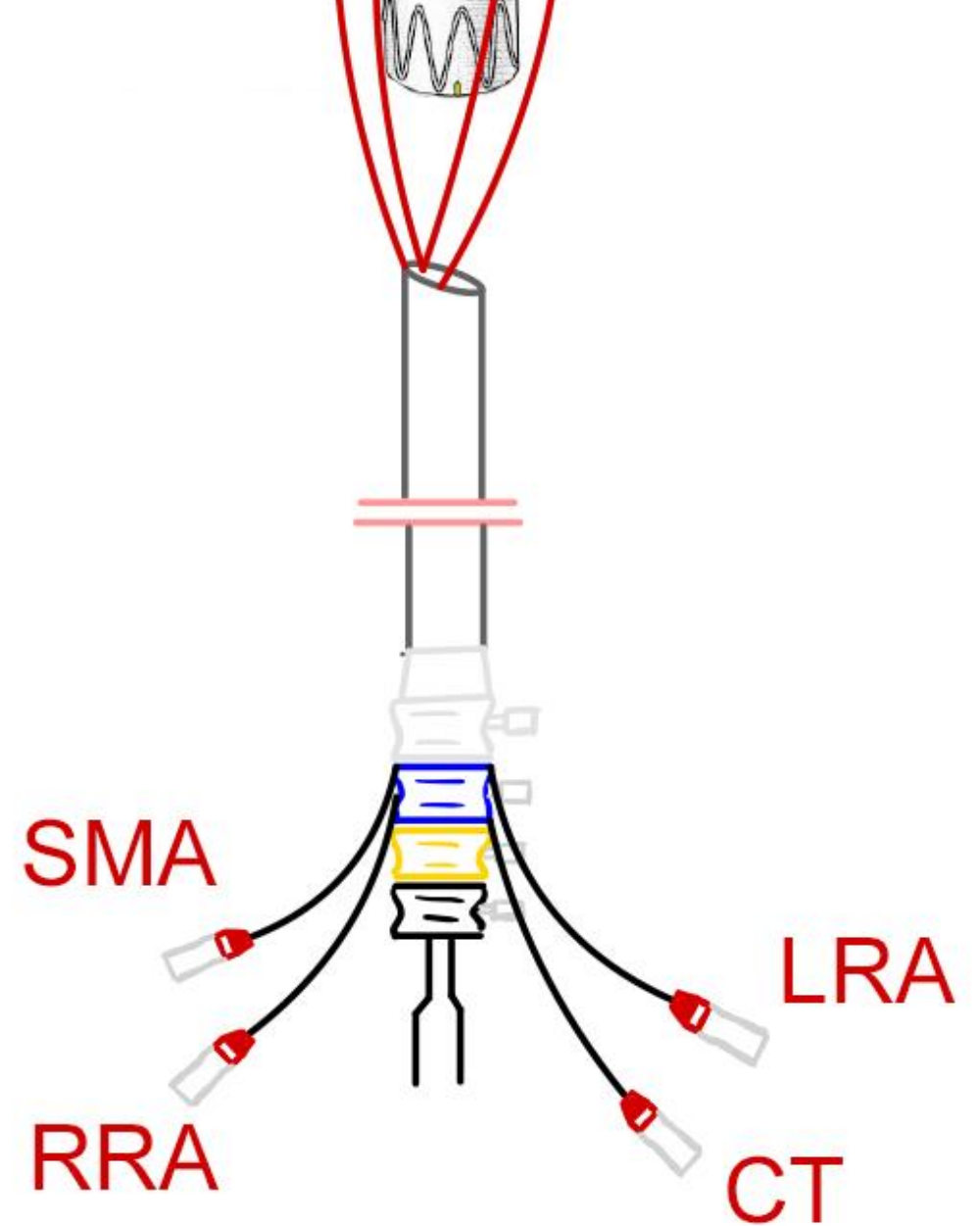
Positioning the t-Branch

- Cannulating the false lumen
- Creating a re-entry tear
- Cannulate the TEVAR
- Deploy the t-Branch



Preloaded T-Branch

1. Snare **4 m Terumo guidewire**
2. Through-and-through
3. Cut the emerging guidewires
4. Exchange for **8F x 90 cm**
Cook Flexor Shuttle sheath
5. Cannulate



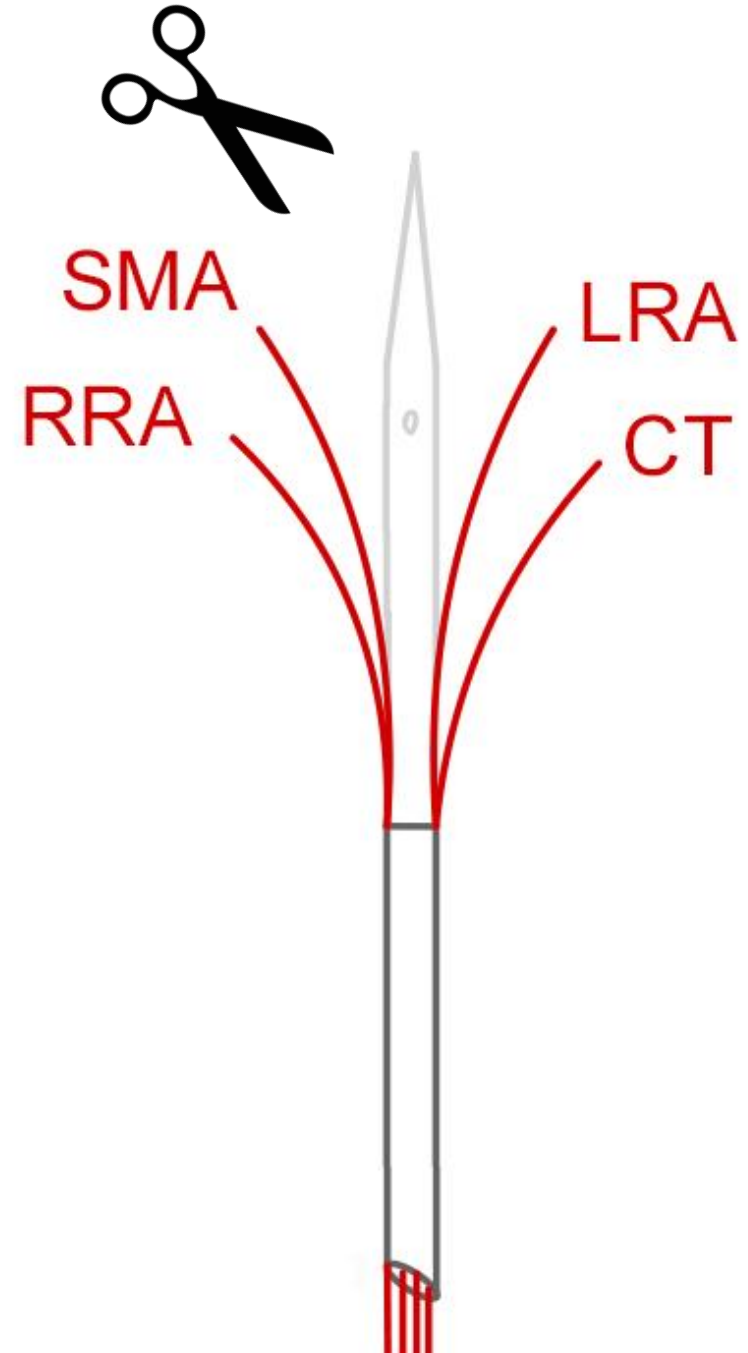
Preloaded T-Branch

1. Snare **4 m Terumo guidewire**
2. Through-and-through
3. Cut the emerging guidewires
4. Exchange for **8F x 90 cm**
Cook Flexor Shuttle sheath
5. Cannulate



Preloaded T-Branch

1. Snare **4 m Terumo guidewire**
2. Through-and-through
3. Cut the emerging guidewires
4. Exchange for **8F x 90 cm**
Cook Flexor Shuttle sheath
5. Cannulate



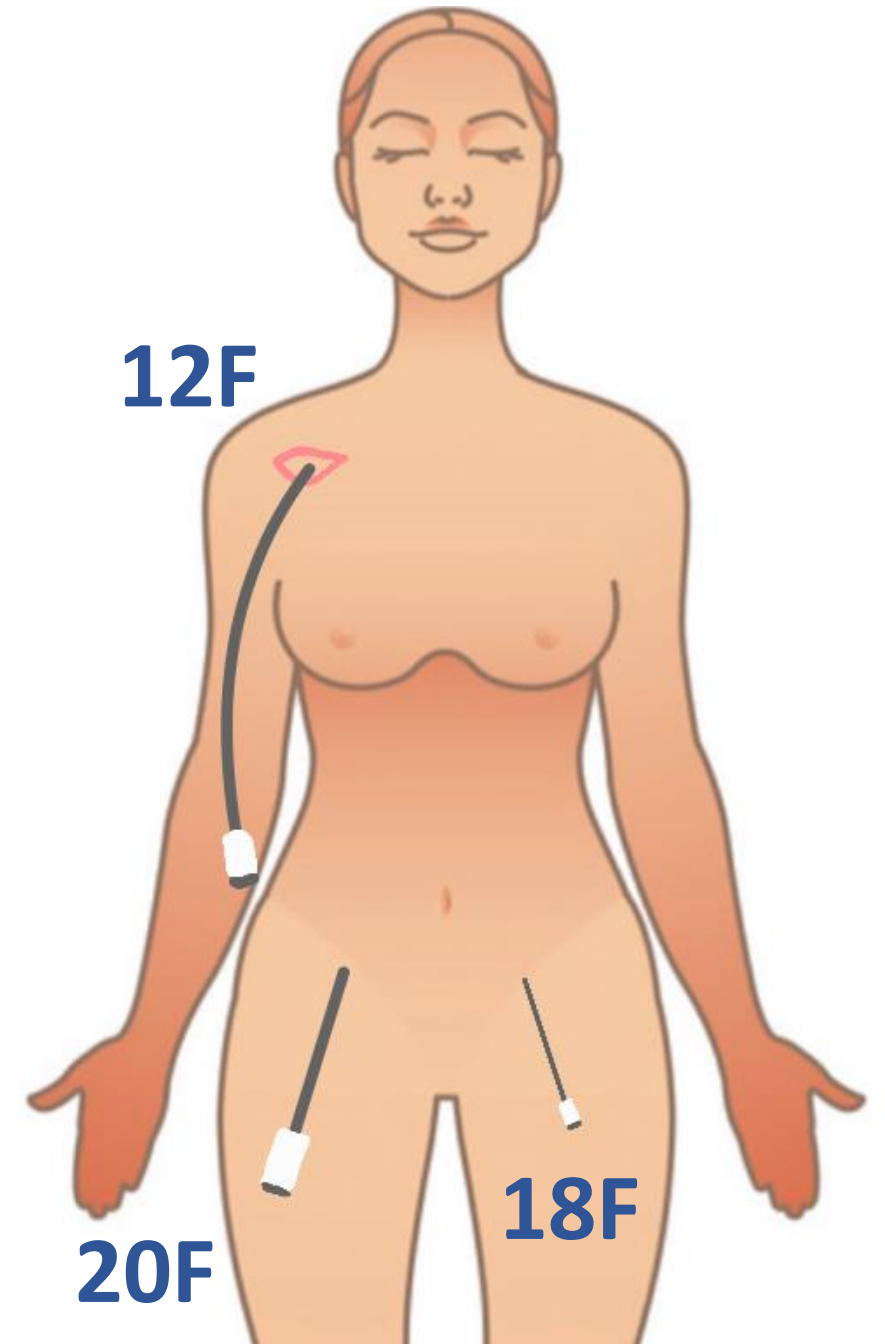
Setup

Gore DrySeal **12F** x 45 cm right axillary

Gore DrySeal **20F** x 33 cm right femoral

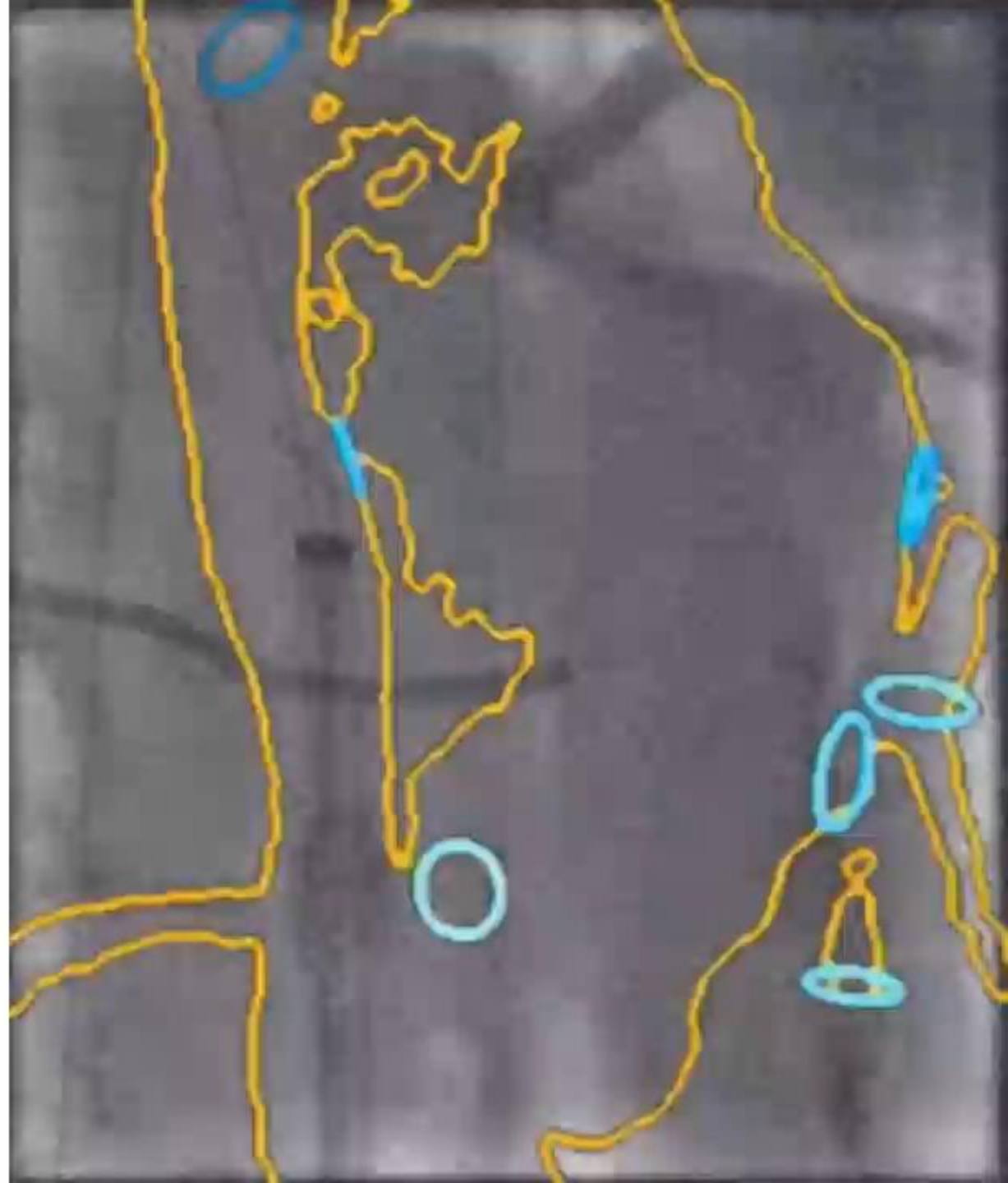
10F short sheath left femoral

Gore DrySeal **18F** x 33 cm left femoral



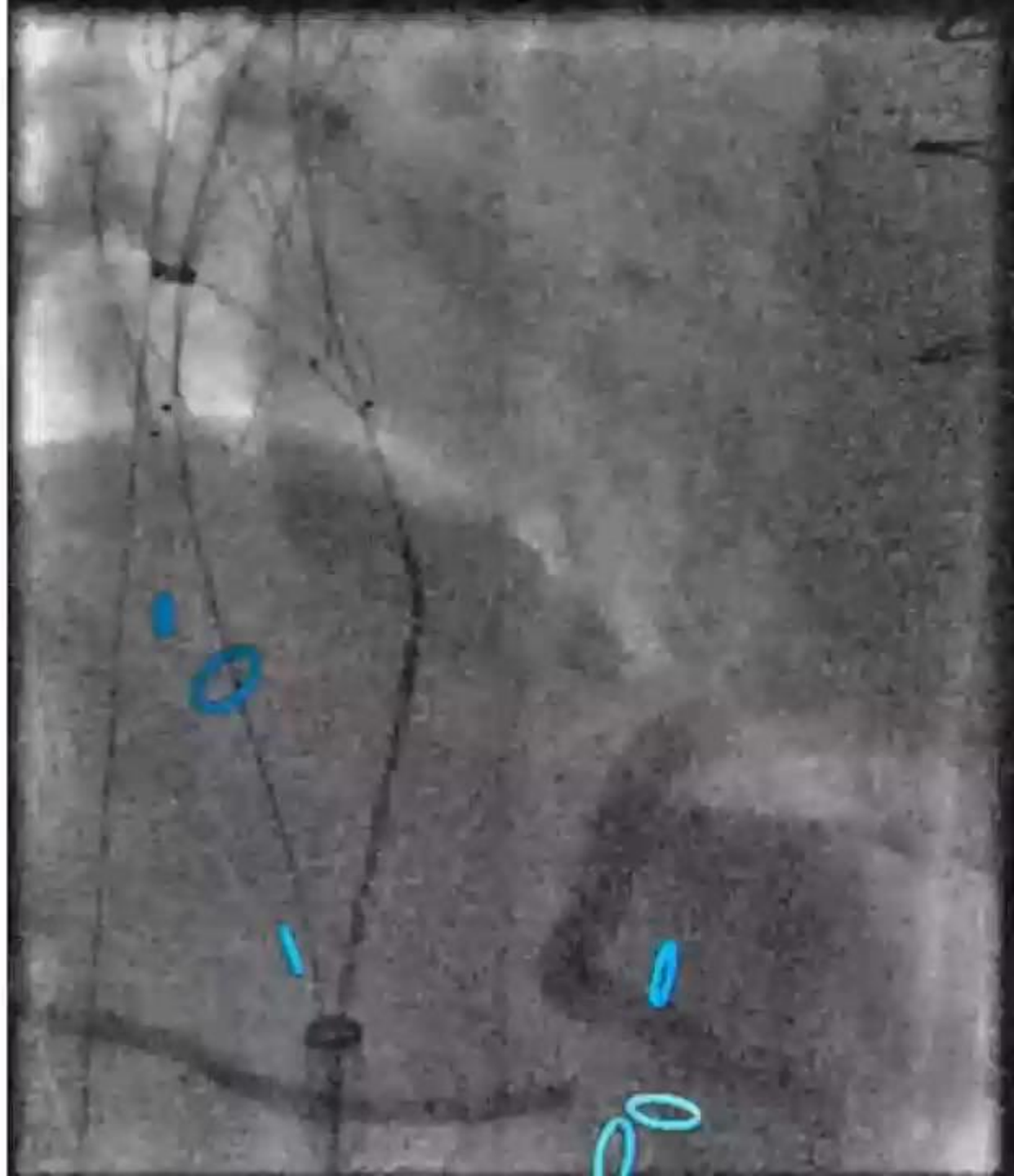
Positioning the t-Branch

- Cannulating the false lumen



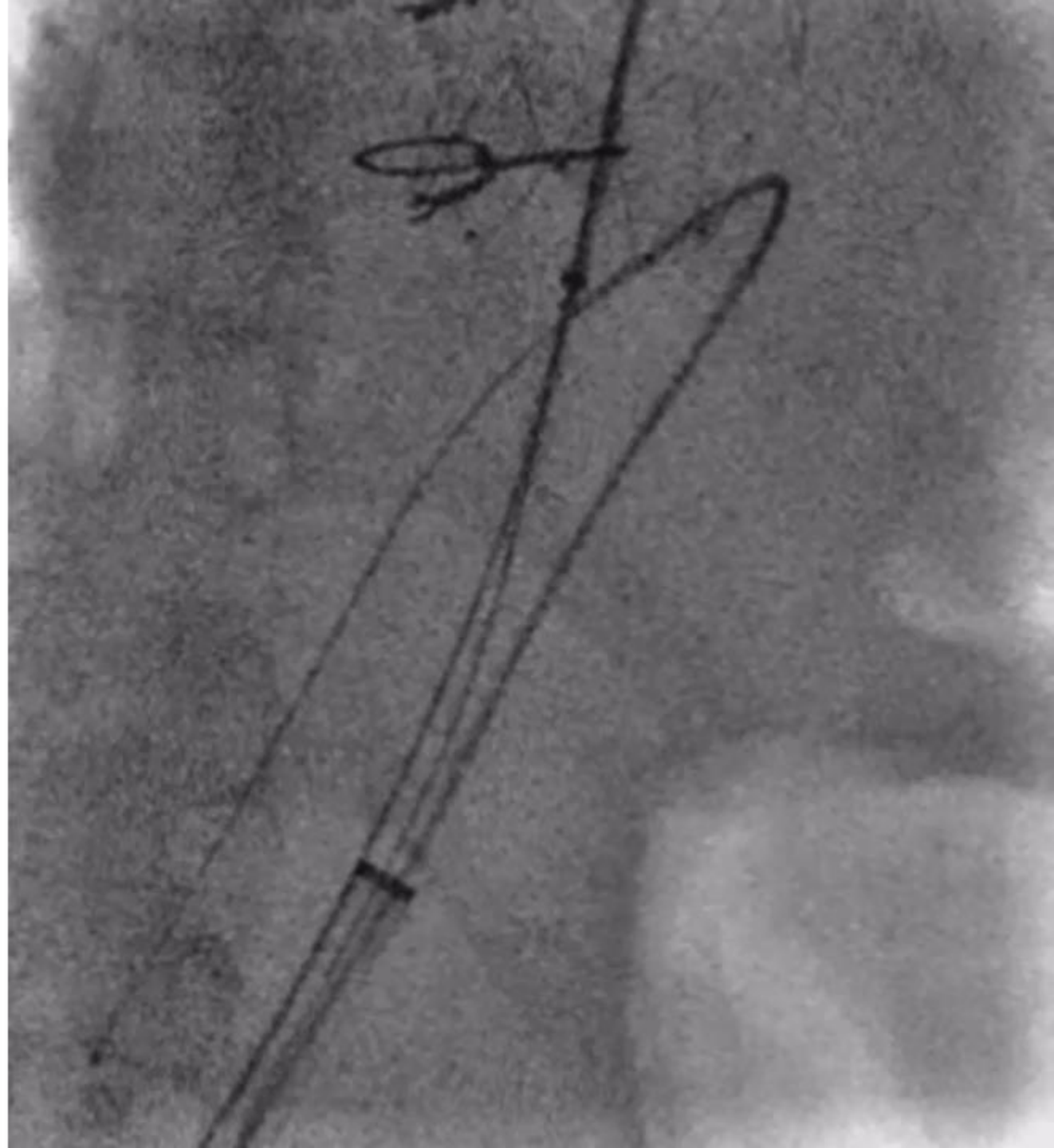
Positioning the t-Branch

- Cannulating the false lumen
- Creating a re-entry tear



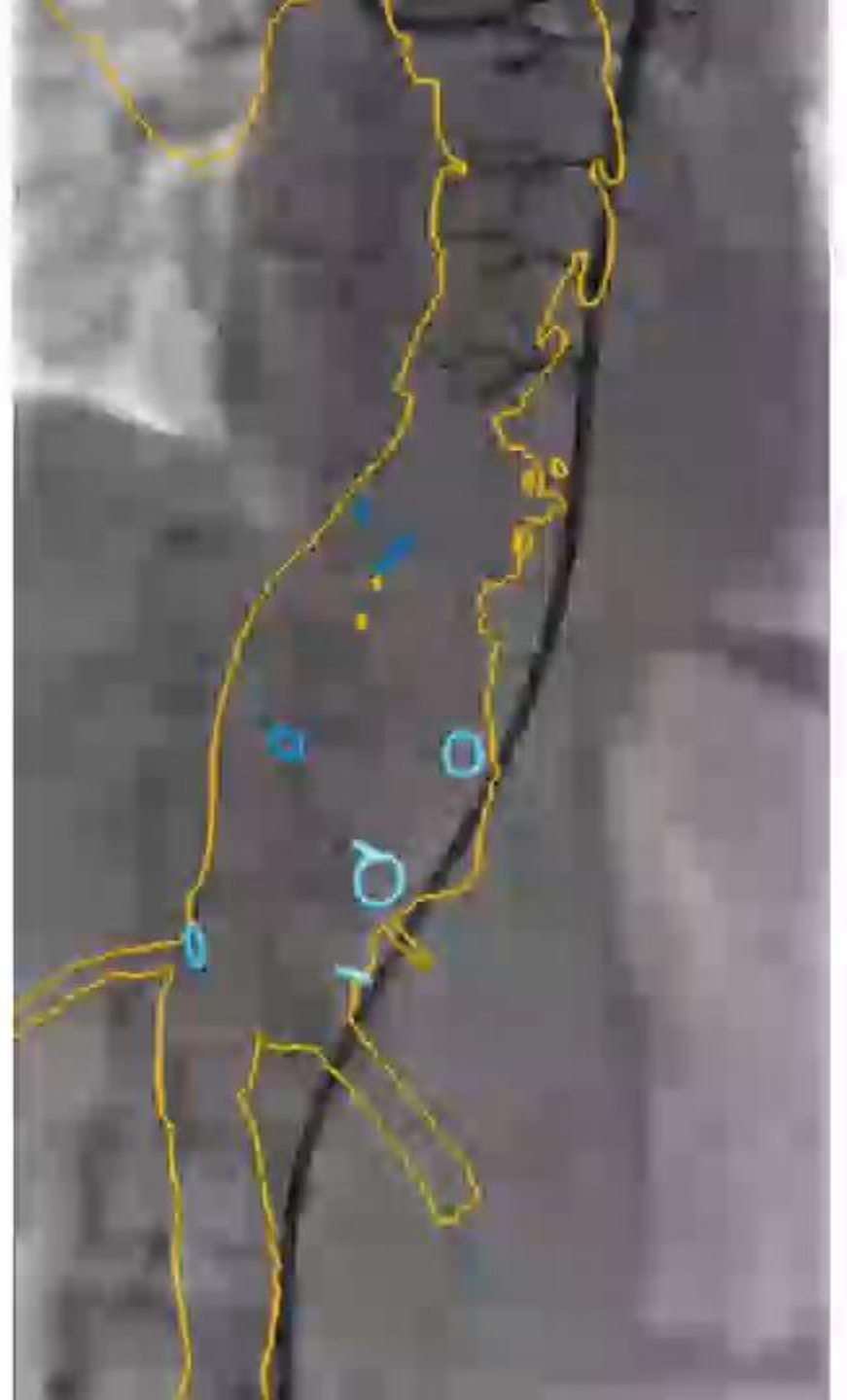Positioning the t-Branch

- Cannulating the false lumen
- Creating a re-entry tear
- Cannulating the TEVAR



Positioning the t-Branch

- Cannulating the false lumen
- Creating a re-entry tear
- Cannulating the TEVAR
- Deploying the t-Branch



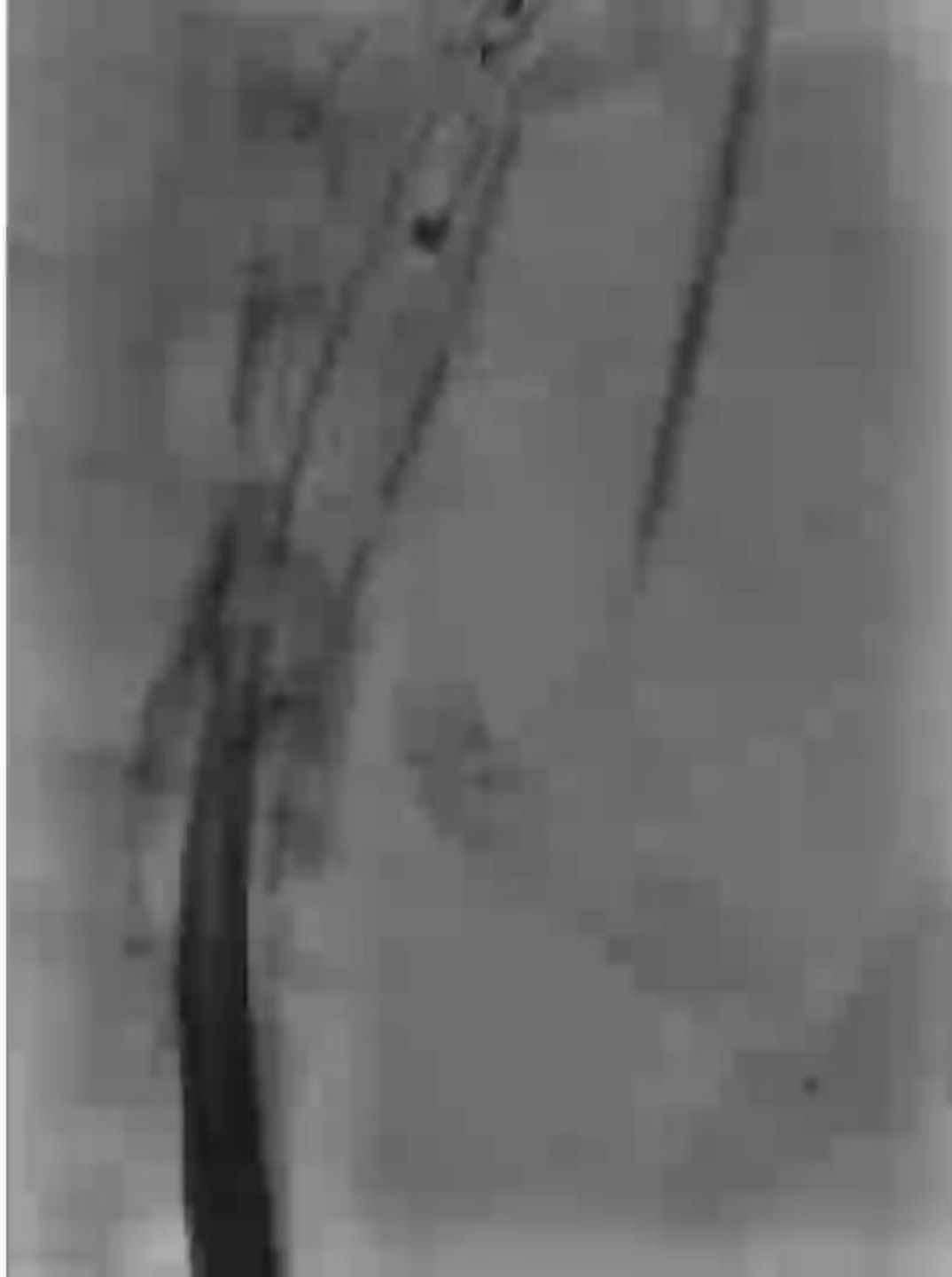Left Renal Artery

- Sheath advancement
Over pre-loaded guidewire



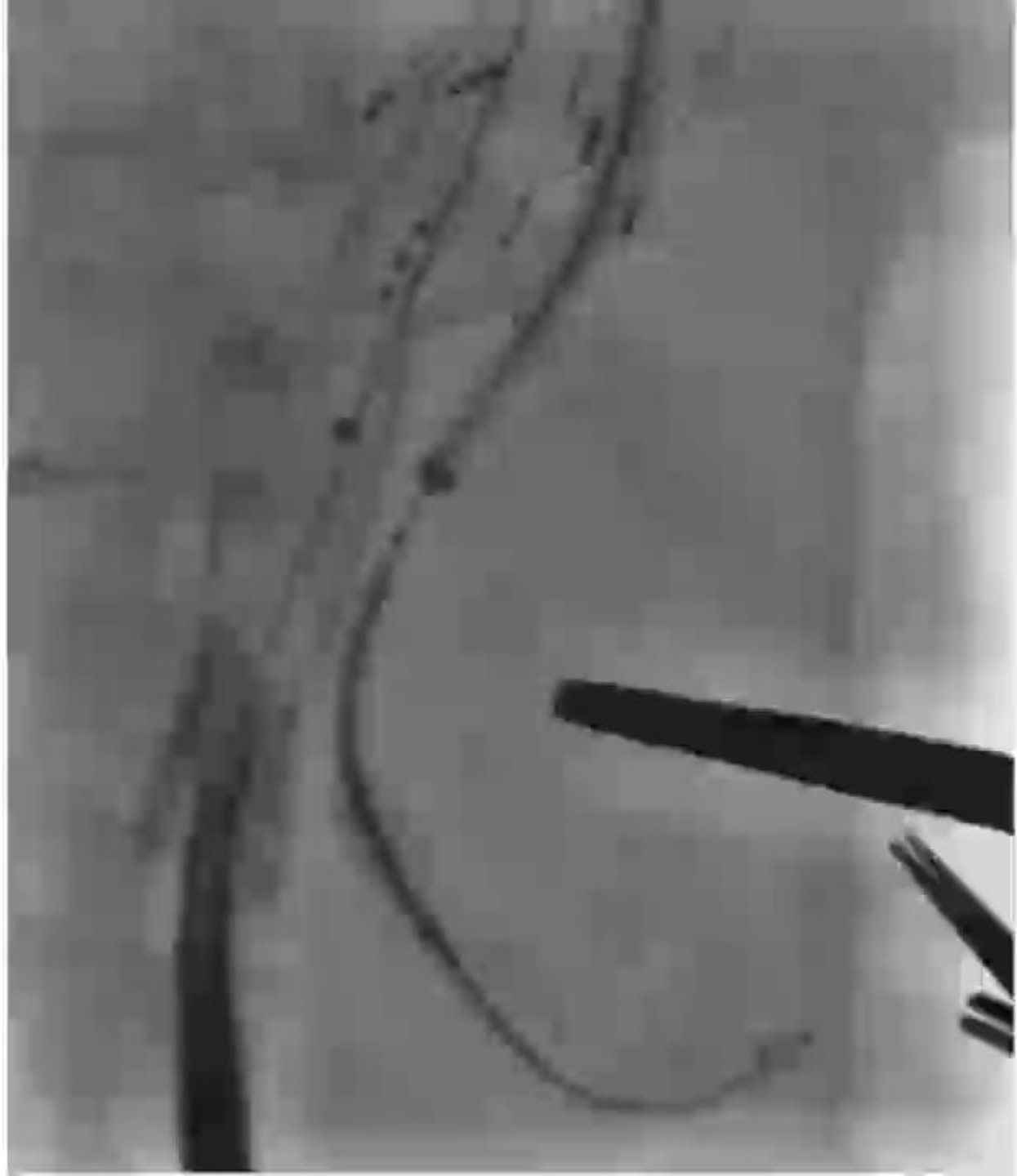
Left Renal Artery

- Sheath advancement
Over pre-loaded guidewire
- Catheterization of renal



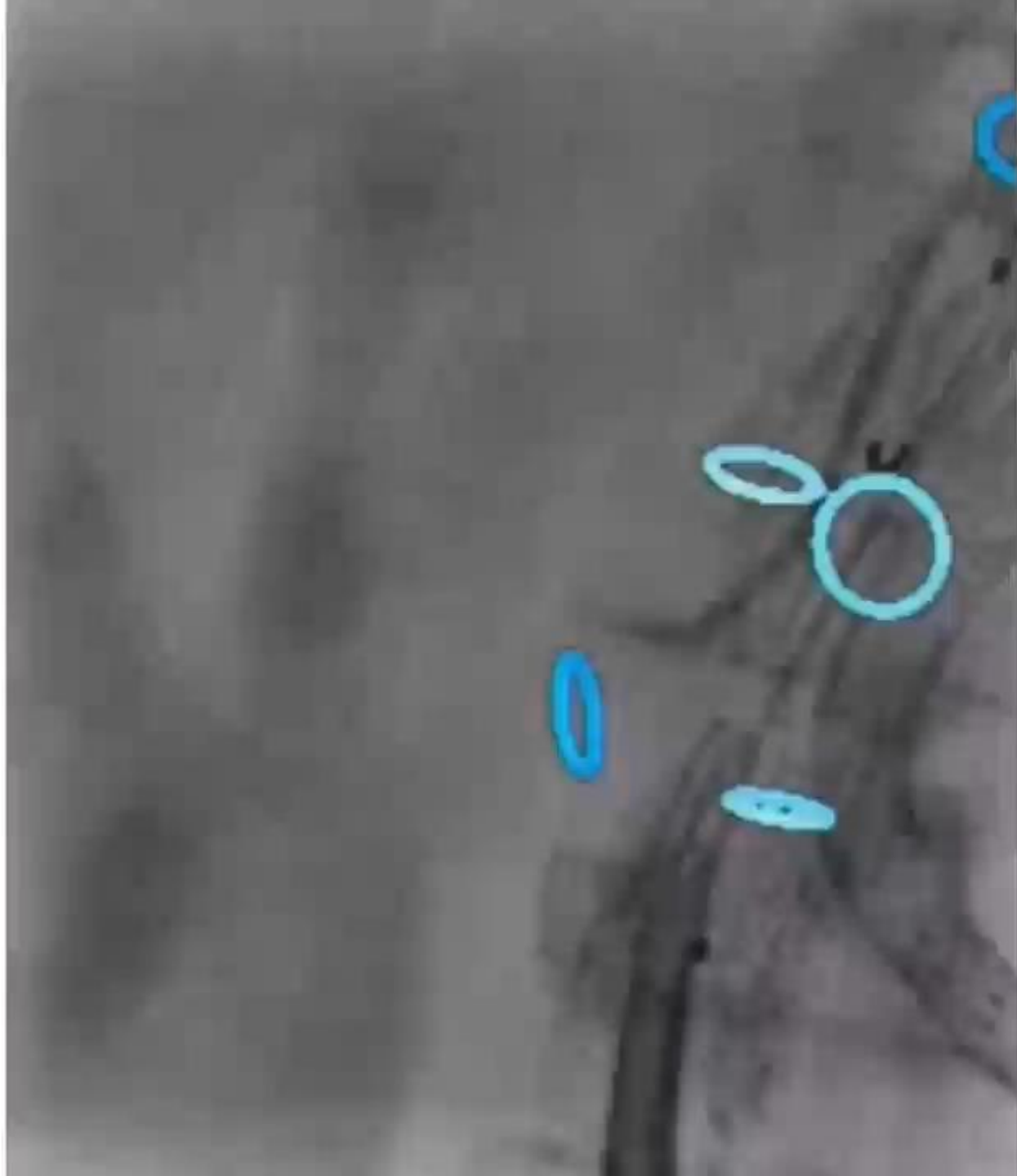
Left Renal Artery

- Sheath advancement
Over pre-loaded guidewire
- Catheterization of renal
- **Bridging Stents**
 - 7 x 57 mm BeGraft
 - 7 x 100 mm Viabahn
 - 7 x 27 mm BeSmooth



Right Renal Artery

- Catheterization of renal



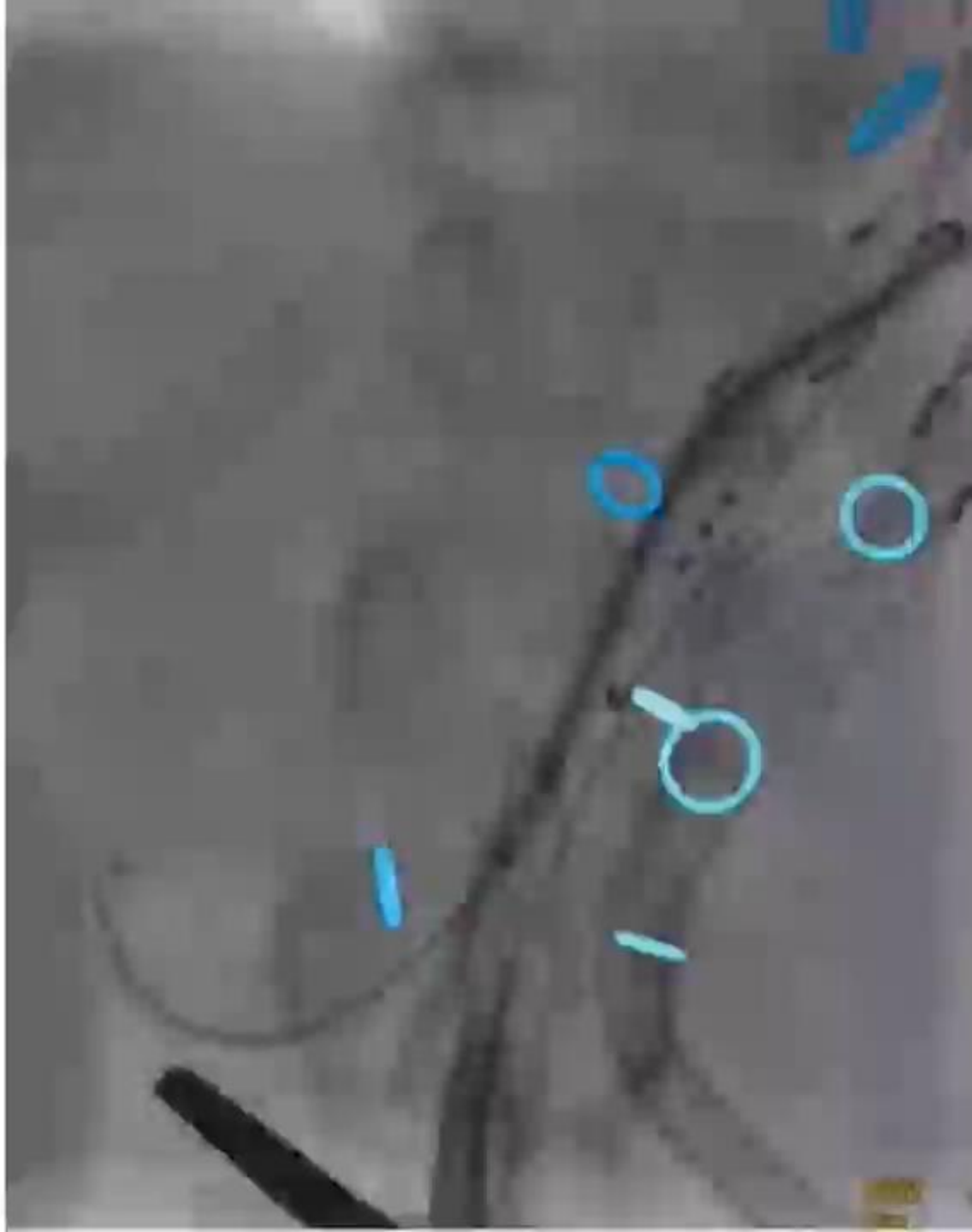
Right Renal Artery

- Catheterization of renal
- Selective angiogram



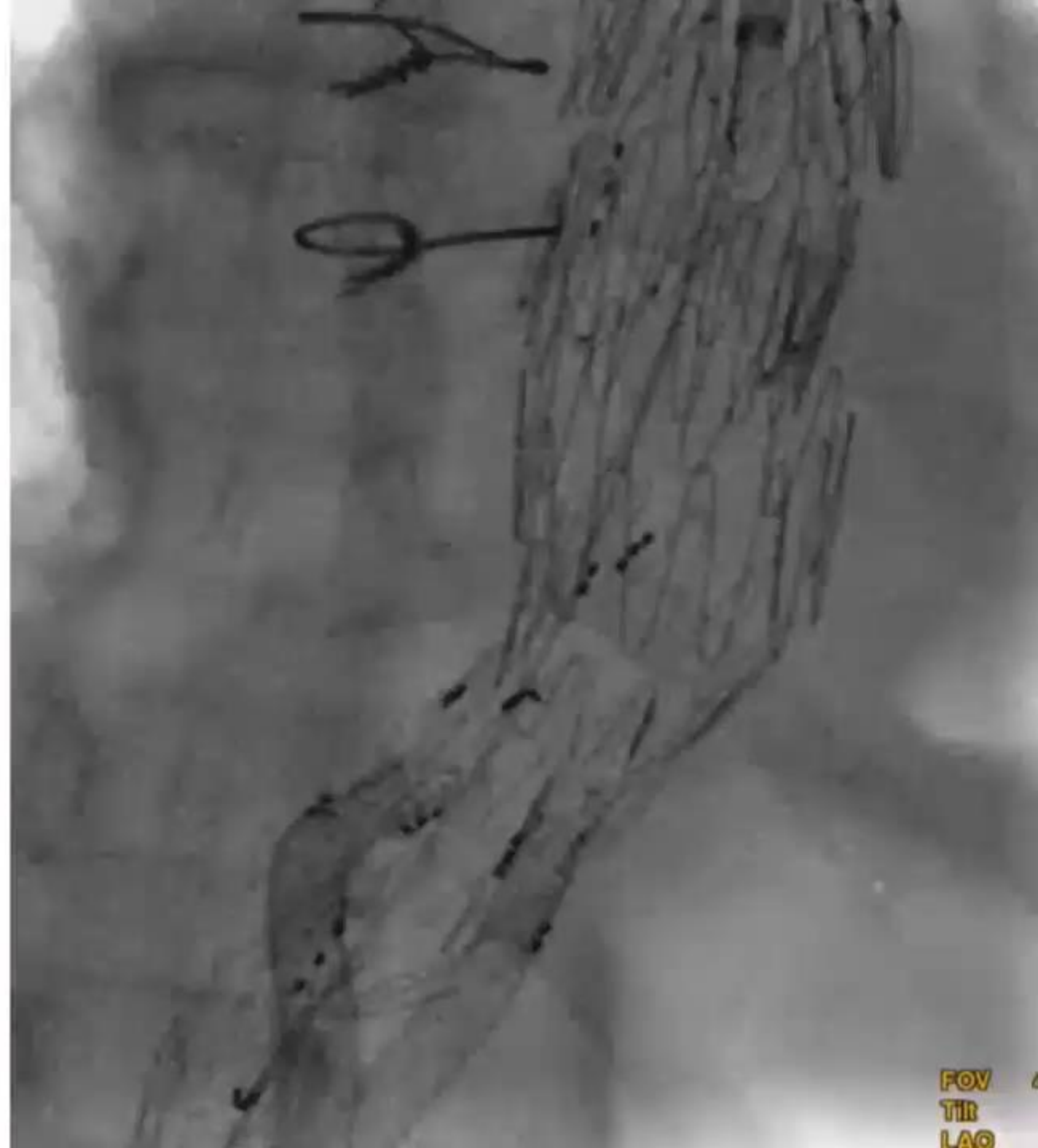Right Renal Artery

- Catheterization of renal
- Selective angiogram
- **Bridging Stents**
 - 8 x 100 mm Viabahn
 - 8 x 57 mm BeGraft
 - 8 x 100 mm Viabahn



Superior Mesenteric Artery

- Catheterization of SMA

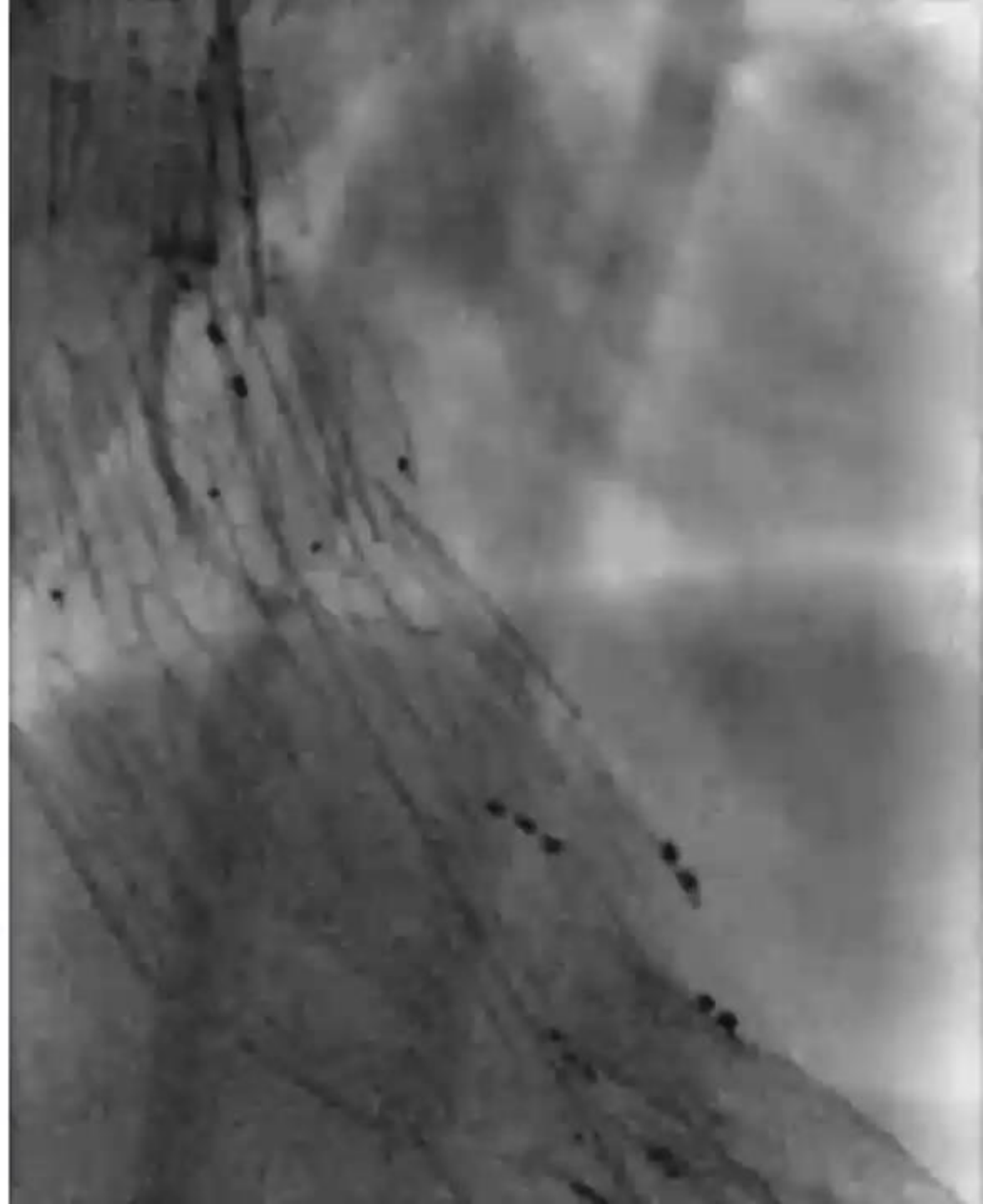


Superior Mesenteric Artery

- Catheterization of SMA
- **Bridging Stents**
 - 9 x 57 mm BeGraft
 - 10 x 100 mm Viabahn
 - 9 x 60 mm Protégé GPS

Celiac Artery

- Catheterization of Celiac



Celiac Artery

- Catheterization of Celiac
- **Bridging Stents**
 - 8 x 57 mm BeGraft
 - 9 x 100 mm Viabahn
 - 9 x 60 mm Protégé GPS

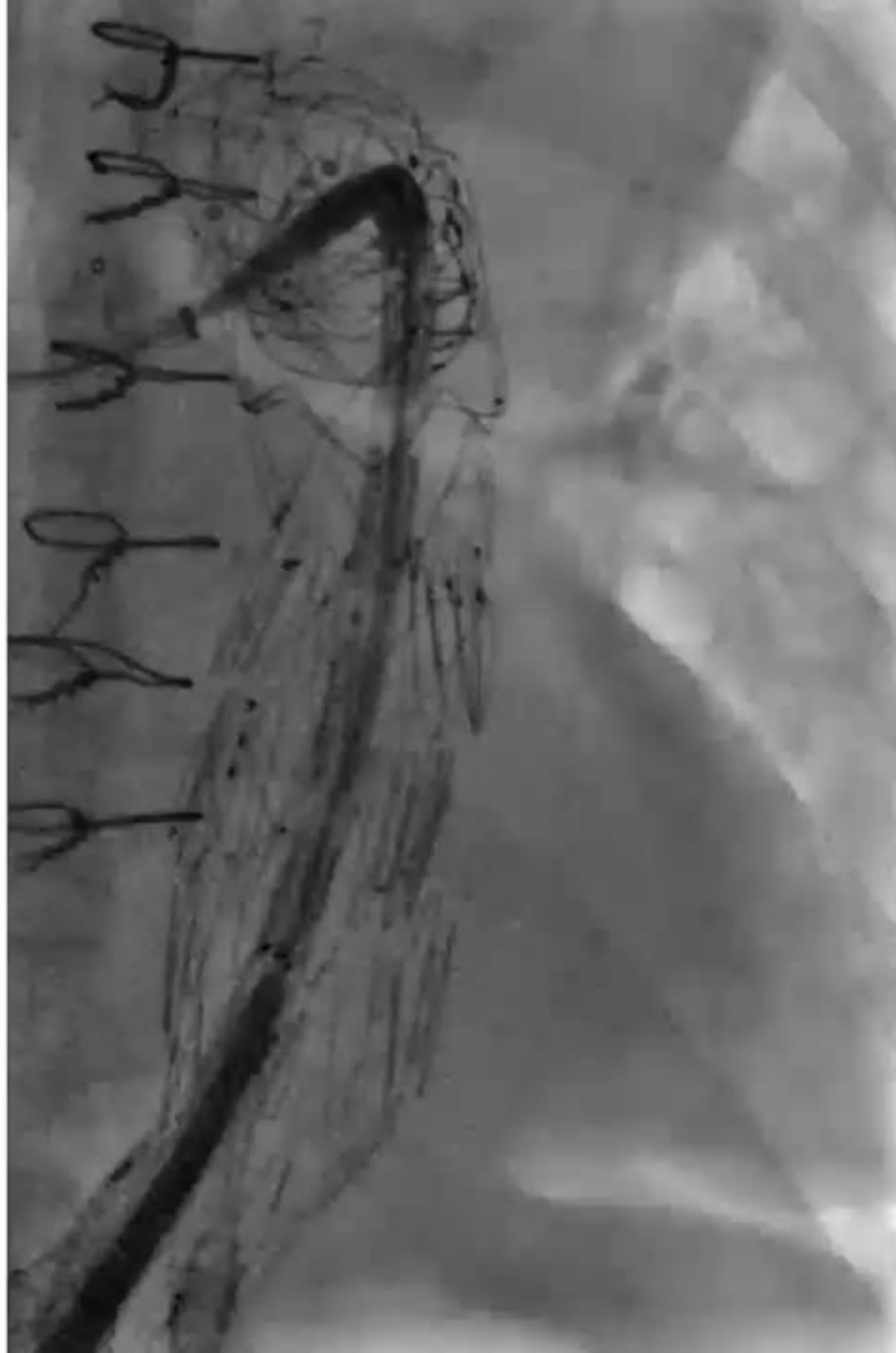Celiac Artery

- Catheterization of Celiac
- **Bridging Stents**
 - 8 x 57 mm BeGraft
 - 9 x 100 mm Viabahn
 - 9 x 60 mm Protégé GPS
- Balloon Molding

Completion TEVAR

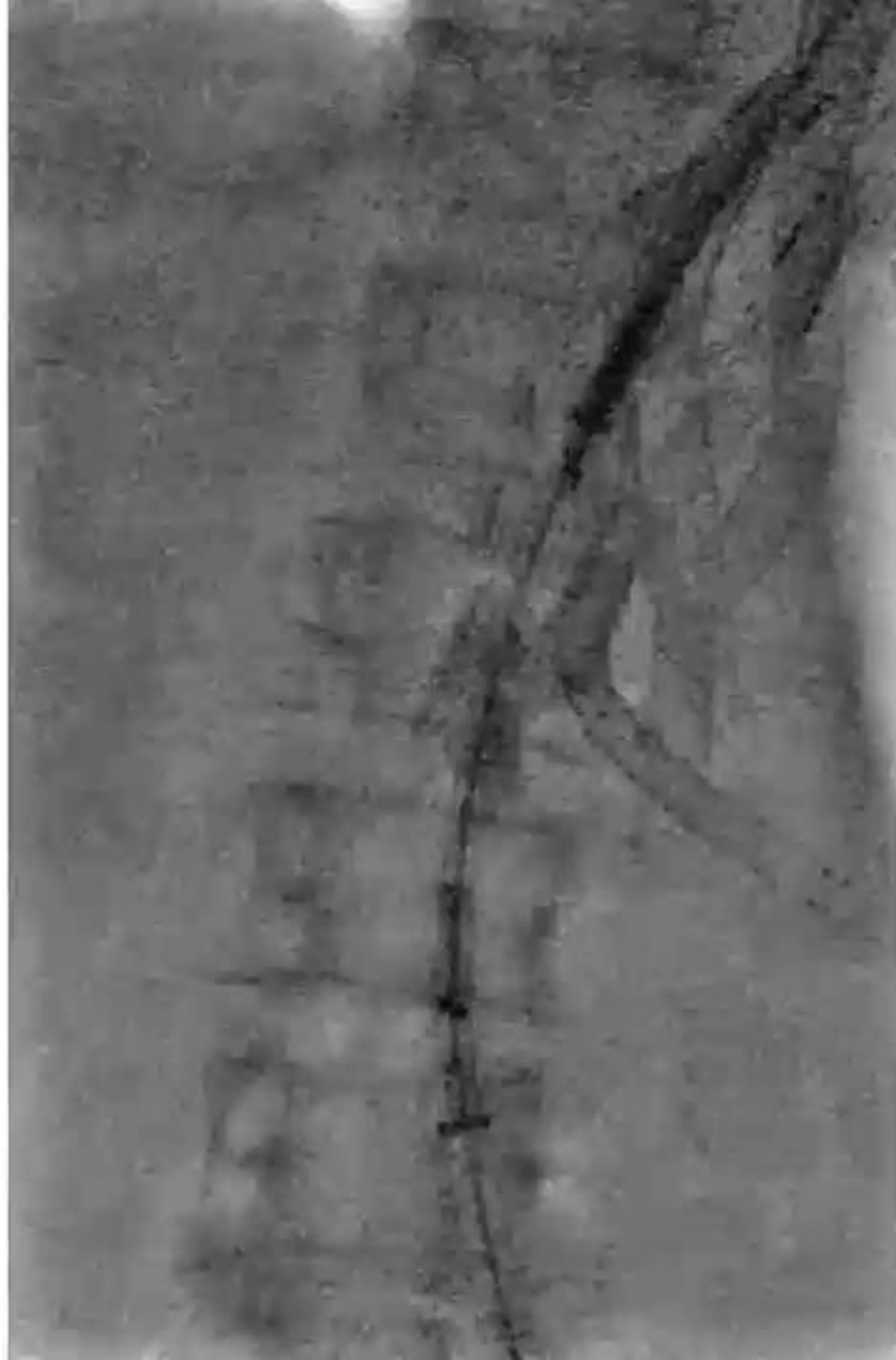
- Proximal overlap

38 x 117 mm Zenith Alpha



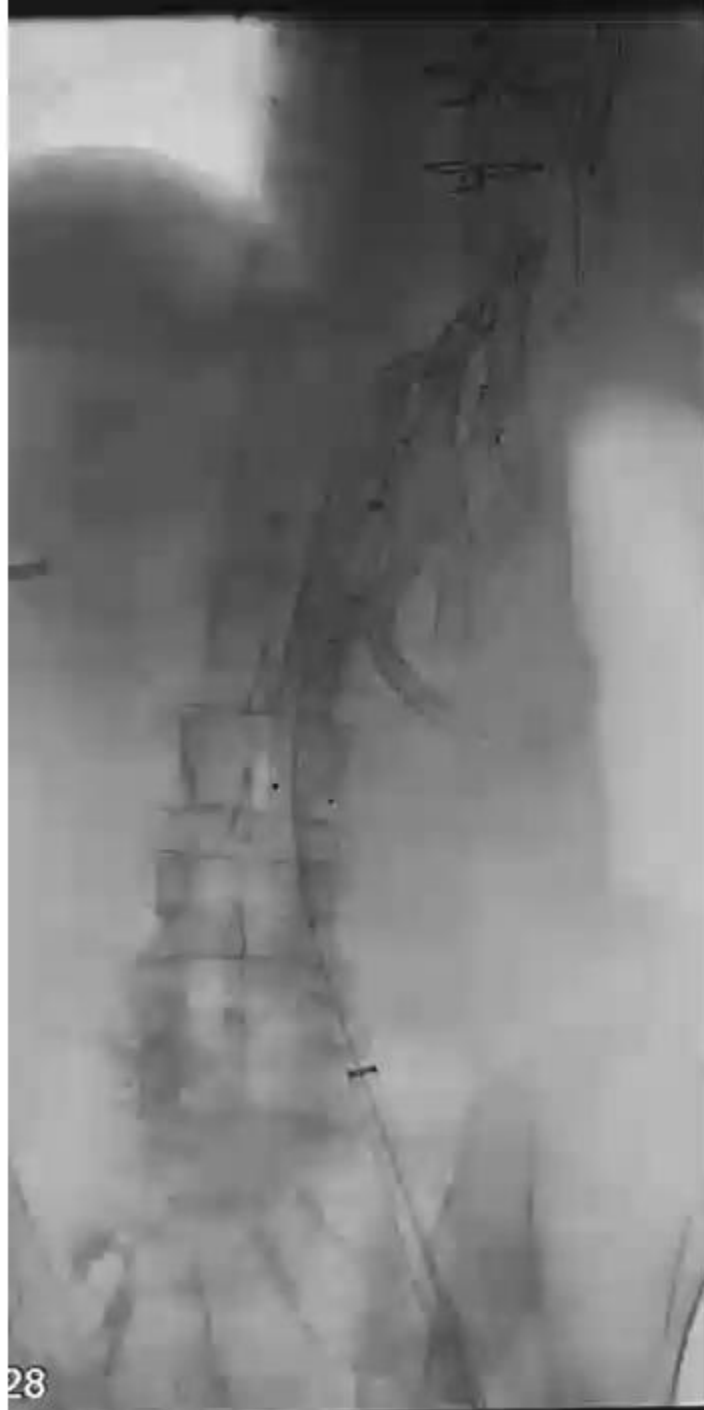Completion TEVAR

- Proximal overlap
 - 38 x 117 mm Zenith Alpha
- Infra-renal aorta
 - 20 x 82 mm Endurant
 - 14 x 39 mm BeGraft Aortic



Completion TEVAR

- Proximal overlap
38 x 117 mm Zenith Alpha
- Infra-renal aorta
20 x 82 mm Endurant
14 x 39 mm BeGraft Aortic
- Completion angiogram



Procedure details

Procedure duration

5 h 35 min

Total contrast volume

60 mL

Fluoroscopy time

110 min

Total dose

6283 cGy.cm²

Air kerma

665 mGy



Postoperative CT angiogram

