

A background image of the Paris skyline at sunset, featuring the Eiffel Tower on the left and various skyscrapers in the distance. The sky is a mix of orange, yellow, and pink.

THE 24TH INTERNATIONAL EXPERTS SYMPOSIUM

CRITICAL ISSUES

IN AORTIC ENDOGRAFTING

DECEMBER 17 & 18 2021

TRIPLE-BRANCHED ENDOGRAFTS ARE MY FAVOURITE OPTION



R.H. (Robin) Heijmen, MD PhD

Department of Cardiothoracic surgery

St. Antonius Hospital Nieuwegein

The Netherlands

TRIPLE-BRANCHED ENDOGRAFTS ARE MY FAVOURITE OPTION



R.H. (Robin) Heijmen, MD PhD

DISCLOSURE

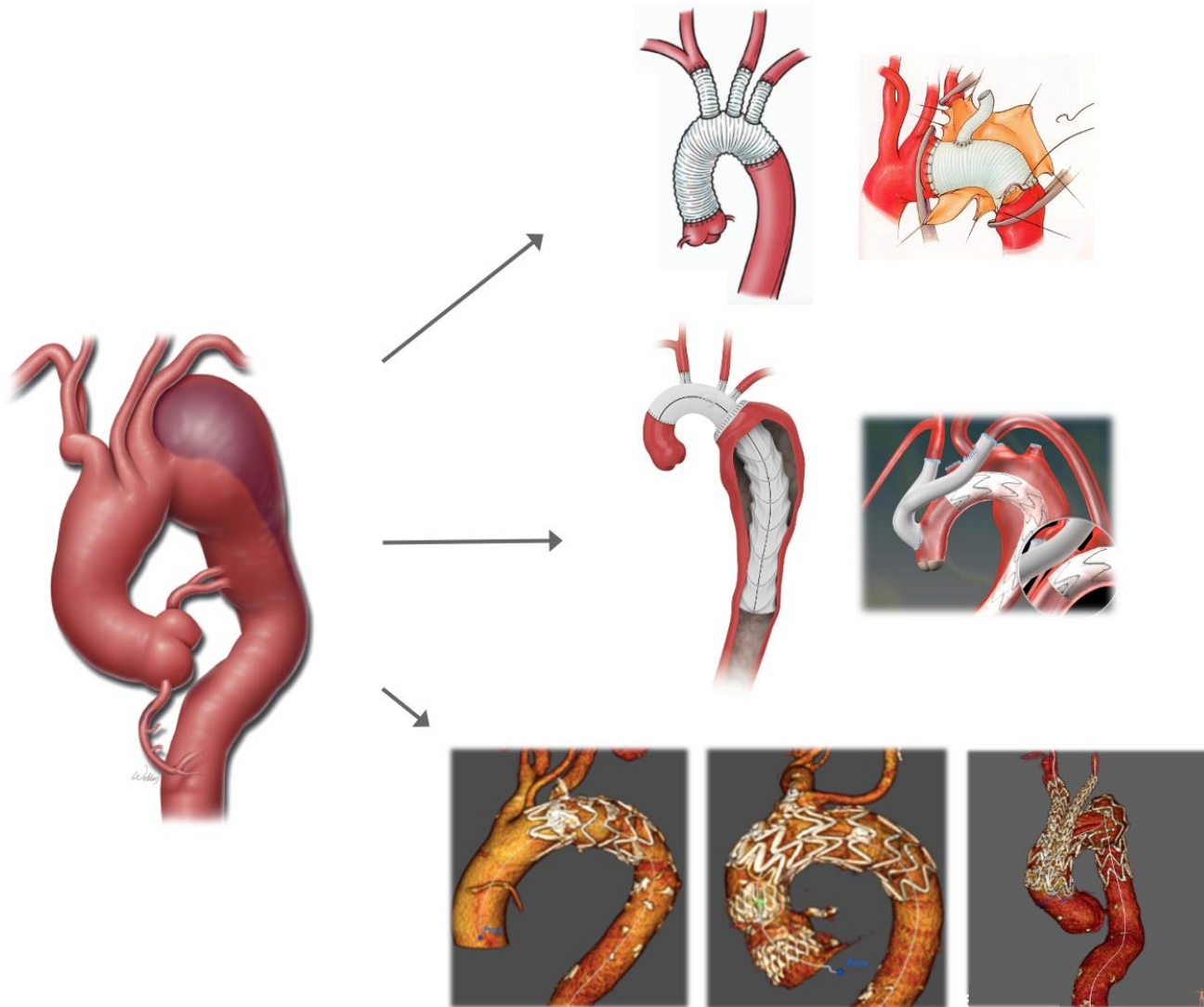
Consultant for Medtronic / Terumo Aortic / WL Gore

CRITICAL ISSUES

IN AORTIC ENDOGRAFTING

DECEMBER 17 & 18 2021

PULLMAN PARIS BERCY PARIS - FRANCE



OPEN repair

OPEN repair

OPEN repair

OPEN repair

HYBRID repair

HYBRID repair

HYBRID repair

HYBRID repair

HYBRID repair

HYBRID repair

HYBRID repair

ENDOASCULAR

ENDOASCULAR

ENDOASCULAR

ENDOASCULAR repair

ENDOASCULAR

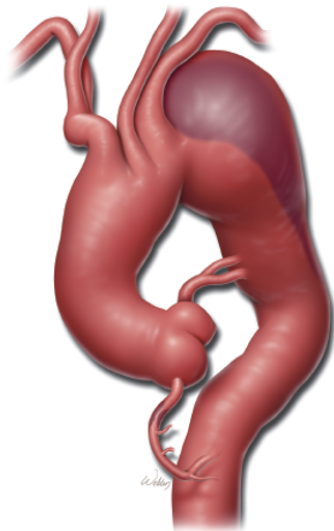ENDOASCULAR

ZIEKENHUIS

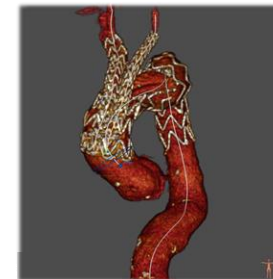
ST ANTONIUS

AORTIC ARCH

remains one of the most complex operative challenges




- . Elderly, frail patients
- . Multiple comorbidities
- . Redo sternotomy
-



ENDOASCULAR
repair

Least invasive approach ...



Endovascular Treatment of Post Type A Chronic Aortic Arch Dissection With a Branched Endograft

Early Results From a Retrospective International Multicenter Study

Ann Surg 2021;273:997–1003

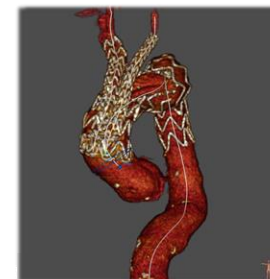

N = 70



Results of endovascular aortic arch repair using the Relay Branch system

European Journal of Cardio-Thoracic Surgery 60 (2021) 662–668

N = 43

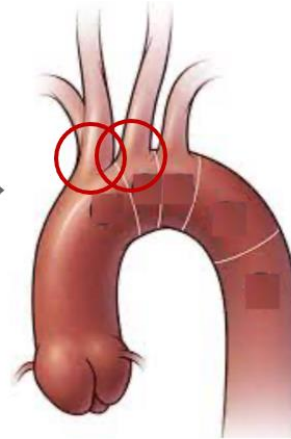


ENDOVASCULAR
repair

Least invasive approach ...

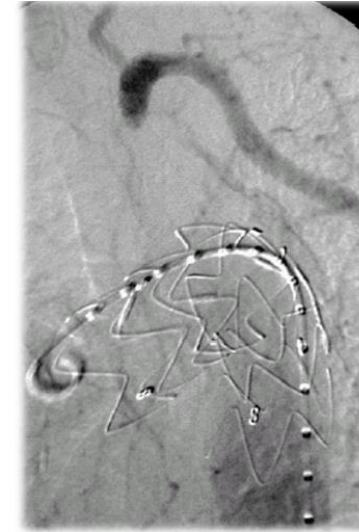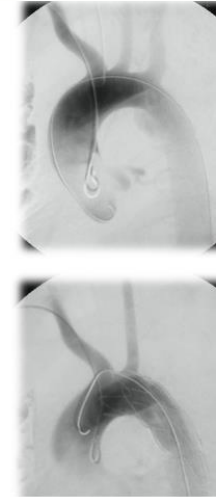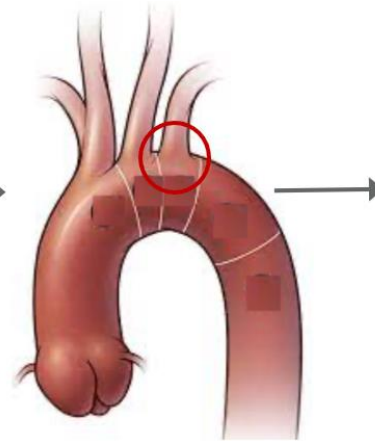


Double
branched ...

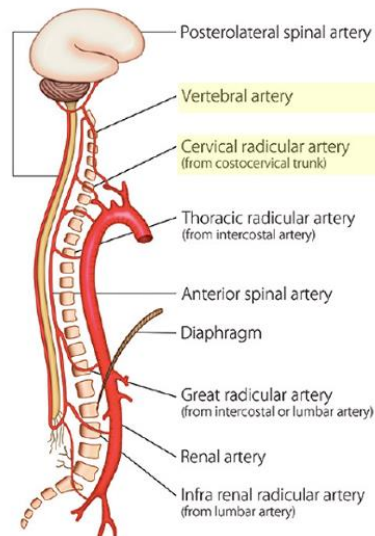




Double branched ...



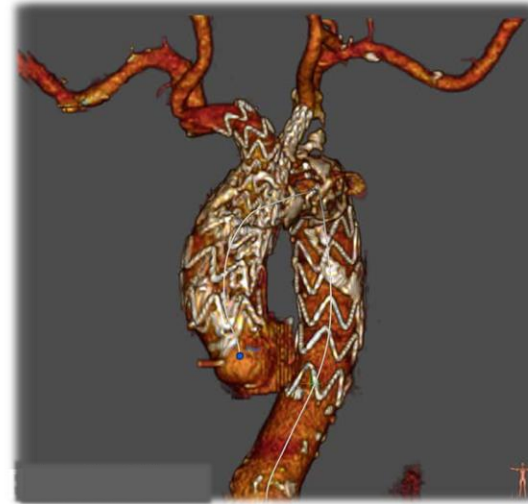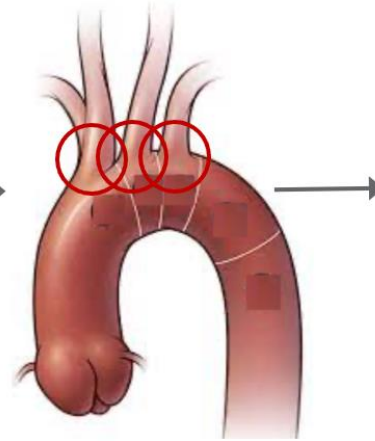
Simply occluding the LSA may result in ...



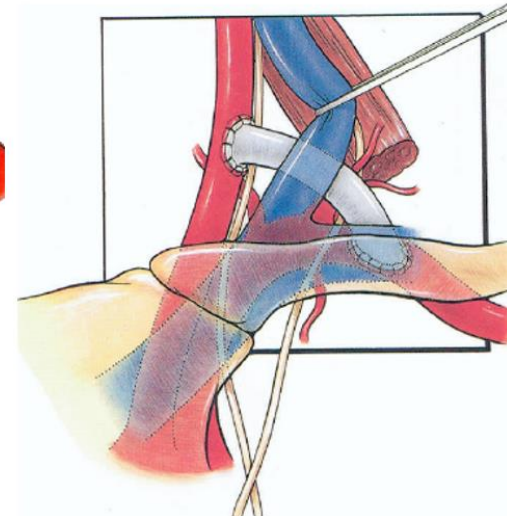
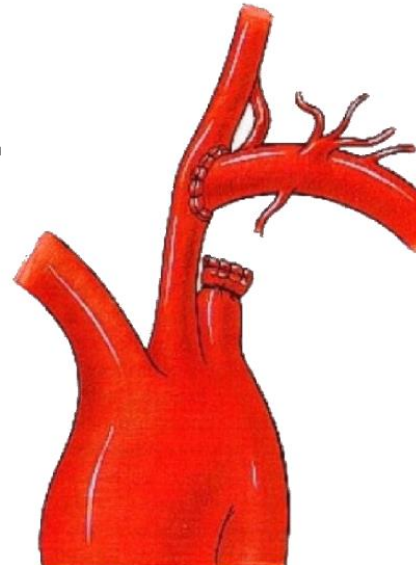
1. left arm malperfusion
2. (posterior) stroke
3. spinal cord ischaemia



Double
branched ...



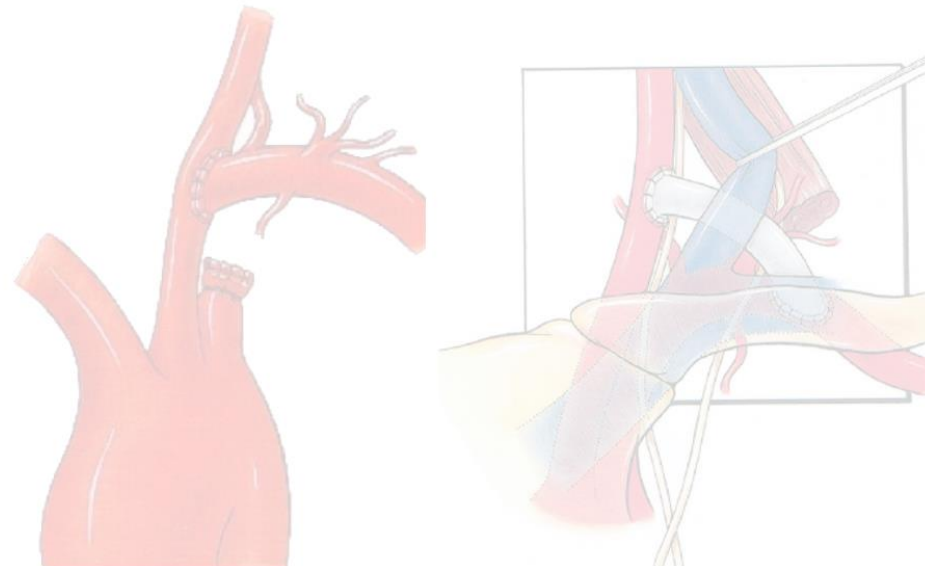
+
LSA - revascularisation ...



Outcomes of carotid-subclavian bypass performed in the setting of thoracic endovascular aortic repair

J Vasc Surg 2019;69:701-9

Complications	No. (%)
Perioperative (n = 112)	
Any phrenic nerve injury (n = 107)	27 (25)
Recurrent laryngeal nerve palsy	6 (5)
Axillary nerve palsy	2 (2)
Neck hematoma	1 (1)
Late (n = 106)	
Anastomotic pseudoaneurysm	2 (2)
Graft ultrafiltration syndrome	1 (1)



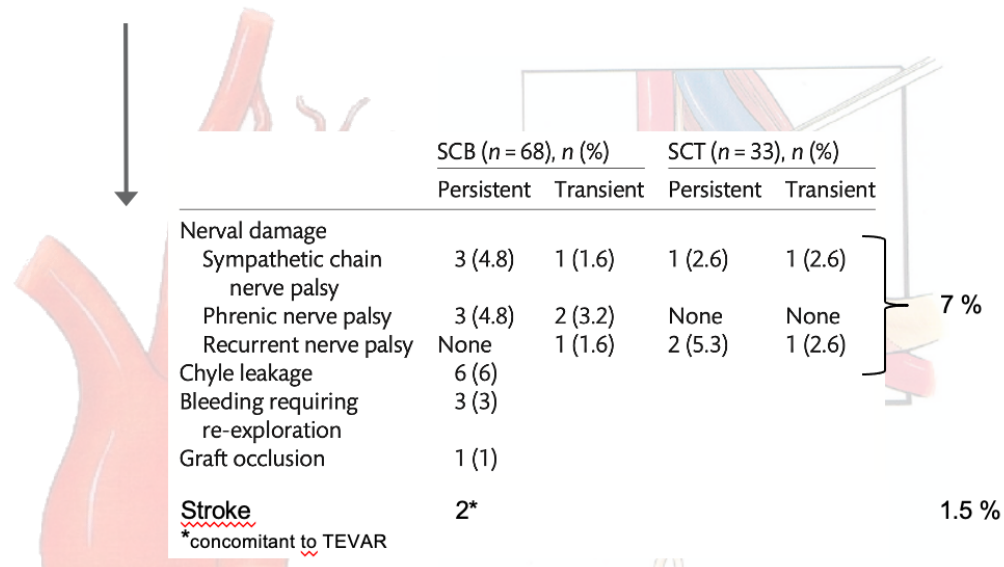
Outcomes of carotid-subclavian bypass performed in the setting of thoracic endovascular aortic repair

J Vasc Surg 2019;69:701-9

Surgical left subclavian artery revascularization for thoracic aortic stent grafting: a single-centre experience in 101 patients[†]

Interactive CardioVascular and Thoracic Surgery 27 (2018) 284–289

Complications	No. (%)
Perioperative (n = 112)	
Any phrenic nerve injury (n = 107)	27 (25)
Recurrent laryngeal nerve palsy	6 (5)
Axillary nerve palsy	2 (2)
Neck hematoma	1 (1)
Late (n = 106)	
Anastomotic pseudoaneurysm	2 (2)
Graft ultrafiltration syndrome	1 (1)

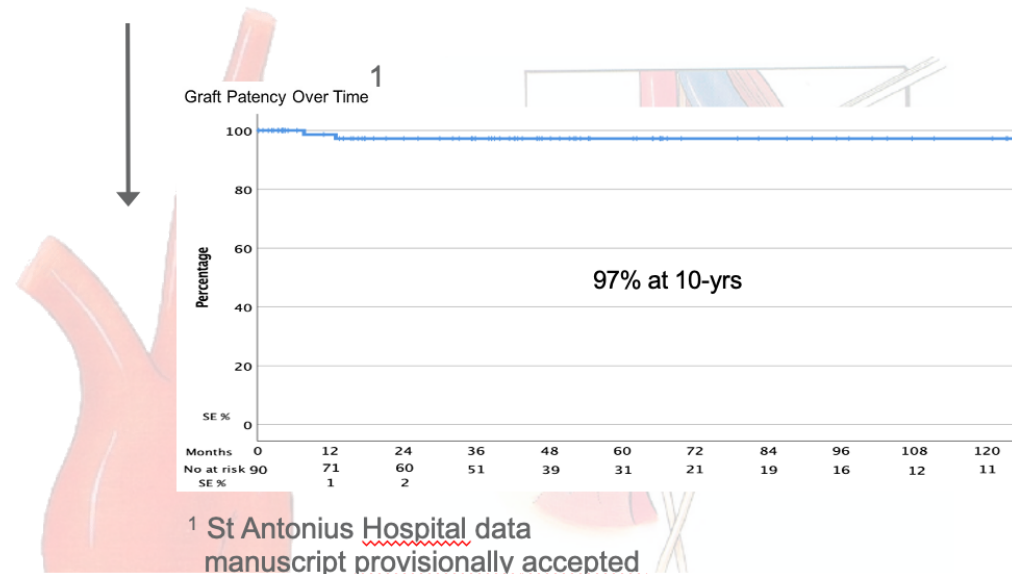
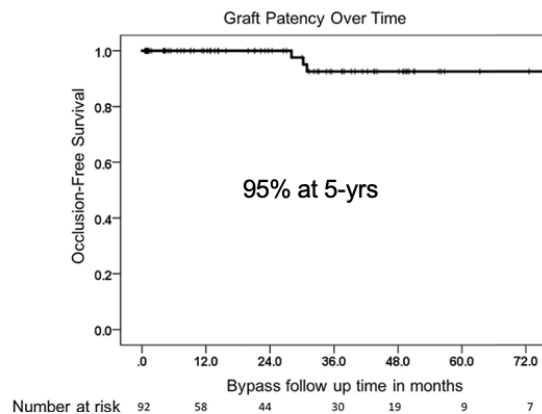


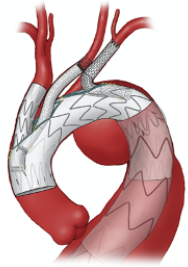Outcomes of carotid-subclavian bypass performed in the setting of thoracic endovascular aortic repair

J Vasc Surg 2019;69:701-9

Surgical left subclavian artery revascularization for thoracic aortic stent grafting: a single-centre experience in 101 patients[†]

Interactive CardioVascular and Thoracic Surgery 27 (2018) 284–289





Multicenter global early feasibility study to evaluate total endovascular arch repair using **three-vessel inner branch stent-grafts** for aneurysms and dissections

Journal of Vascular Surgery
October 2021

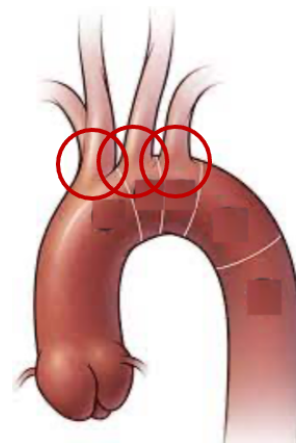
N = 39



Total endovascular aortic arch repair using the Terumo Aortic **triple-branch arch endograft**

Ann Vasc Surg 2021; 000: 1.e1–1.e8

N = 3



M, 78-yrs2010 PCI for MI

2020 PM-DDD

... ↓↓ Pulmonary function :6MWT, O₂ 97 to 84%**DLCO, 33%**

	DLCO
Elevated:	Above 120%
Normal:	80% to 120%
Mildly reduced:	79% to 60%
Moderately reduced:	40% to 59%
Severely reduced:	Below 40%

M, 78-yrs

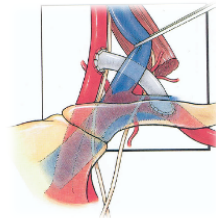
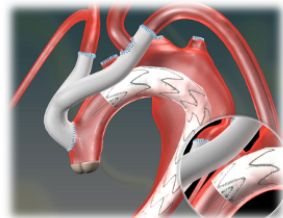
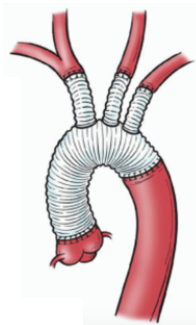
2010 PCI for MI

2020 PM-DDD

... ↓↓ Pulmonary function :

6MWT, O₂ 97 to 84%

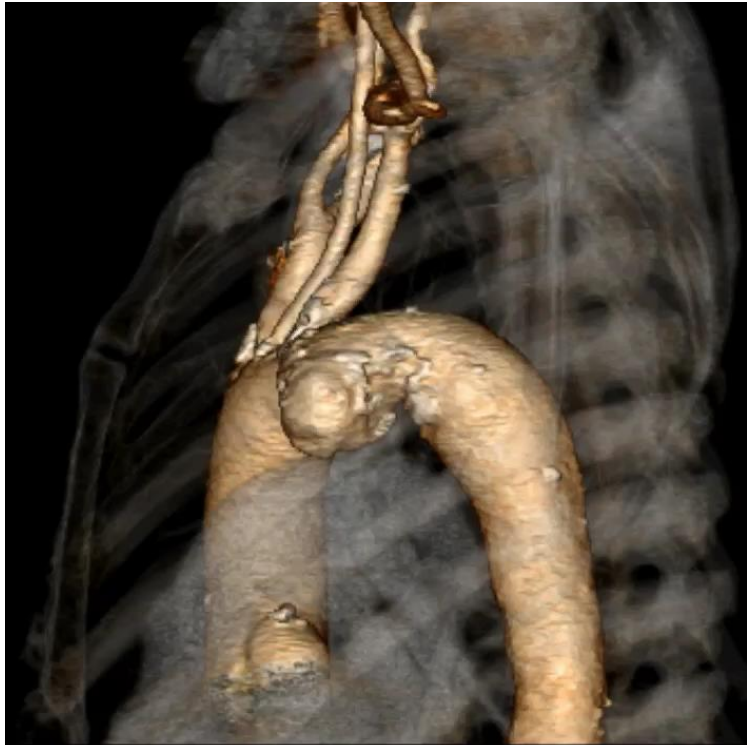DLCO, 33%



	DLCO
Elevated:	Above 120%
Normal:	80% to 120%
Mildly reduced:	79% to 60%
Moderately reduced:	40% to 59%
Severely reduced:	Below 40%

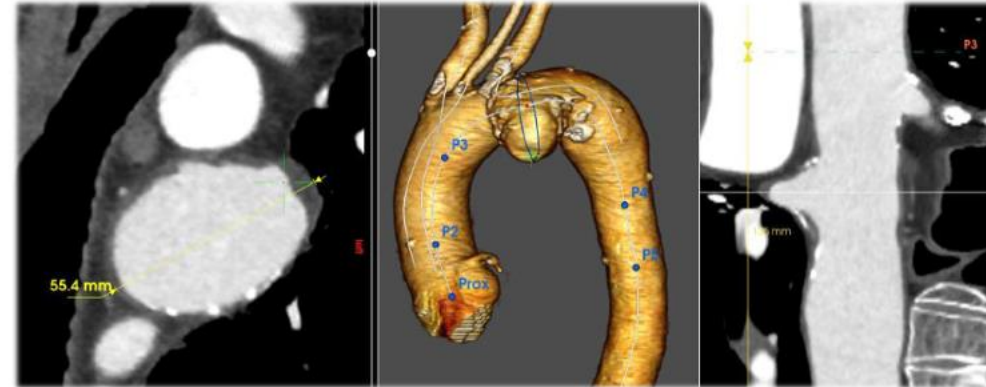
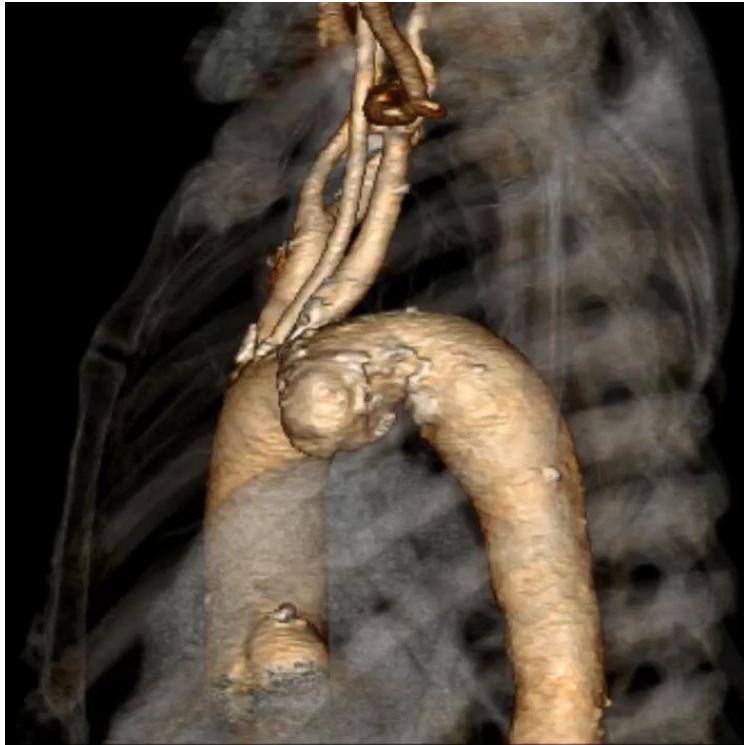M, 78-yrs

Saccular, mid-arch aneurysm (55mm)



M, 78-yrs

Saccular, mid-arch aneurysm (55mm)

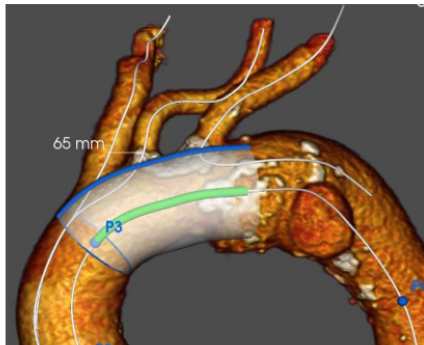


Nót feasible for scallop/ fenestration

General anesthesia possible,
bút truly least-invasive :

Relay[®] TRIPLE-BRANCH

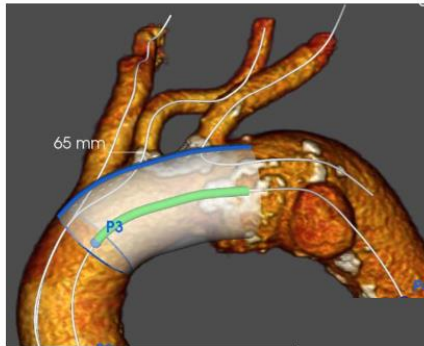Anatomical requirements for Relay[®] TRIPLE-BRANCH



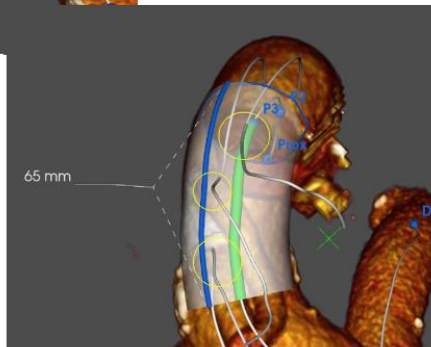
all 3 SATS
should fit inside 65mm window
in length



Anatomical requirements for Relay[®] TRIPLE-BRANCH



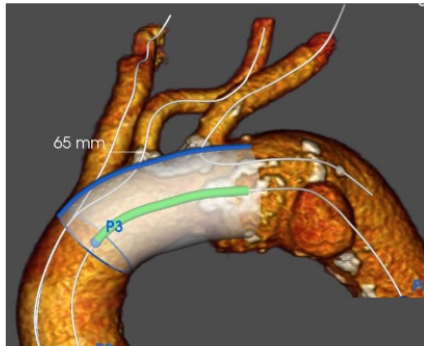all 3 SATS
should fit inside 65mm window
in length



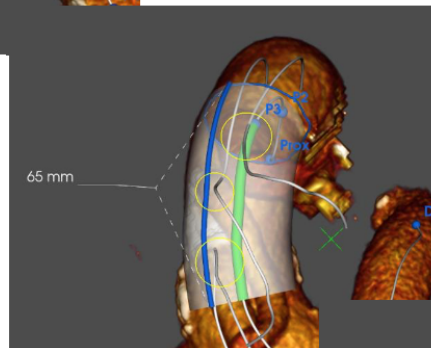
and 26 to 38mm window
in width



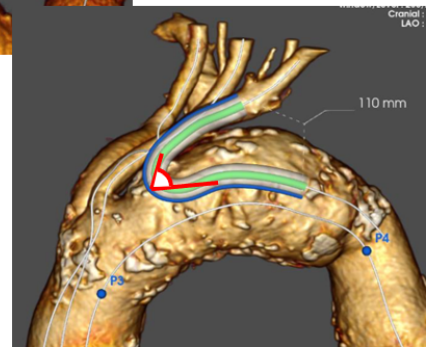
Anatomical requirements for Relay[®] TRIPLE-BRANCH



all 3 SATS
should fit inside 65mm window
in length

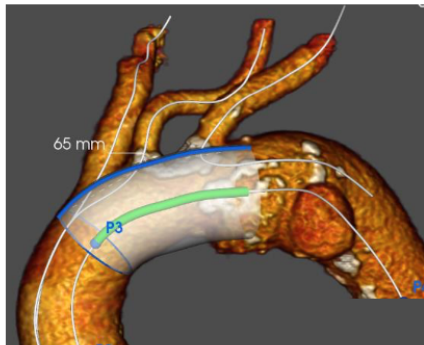


and 26 to 38mm window
in width

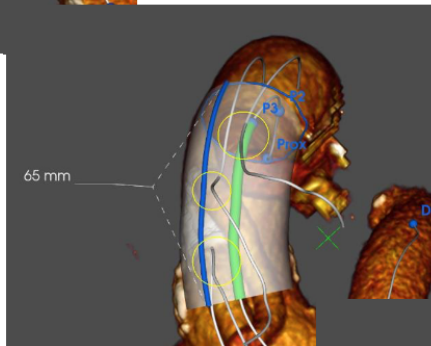


ideally,
LSA transition angle > 75°
after deployment

Anatomical requirements for Relay[®] TRIPLE-BRANCH

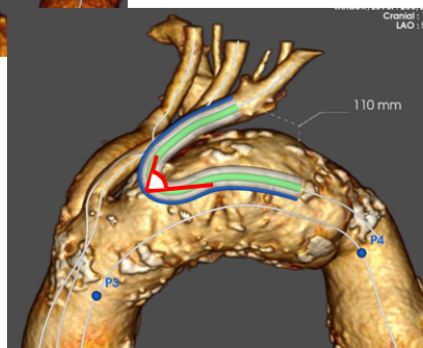


all 3 SATS
should fit inside 65mm window
in length



and 26 to 38mm window
in width

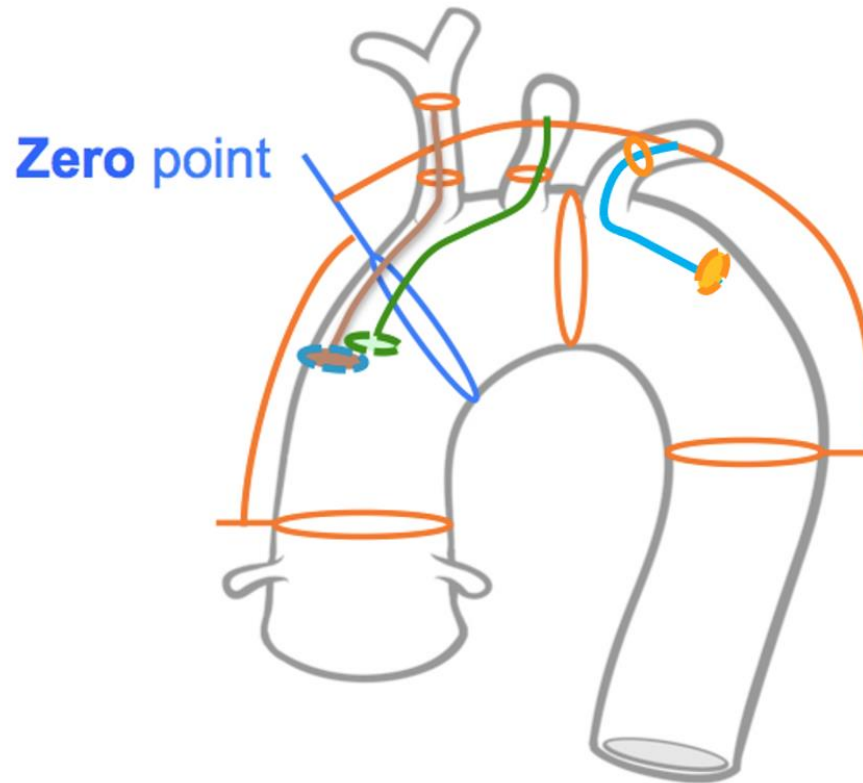
all other
comparable to
Relay[®] DB :



ideally,
LSA transition angle > 75°
after deployment

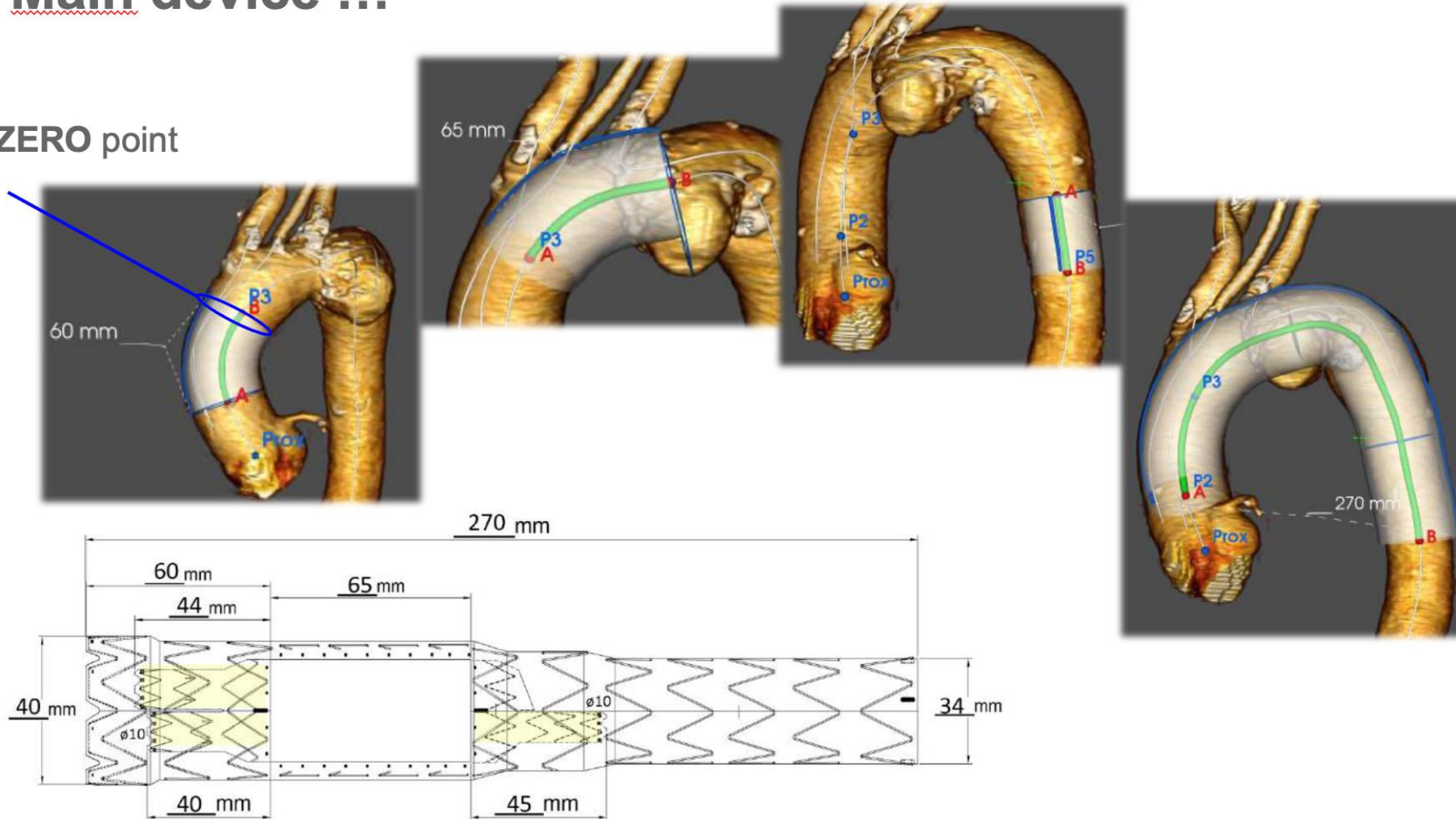


Anatomical requirements for Relay[®] TRIPLE-BRANCH



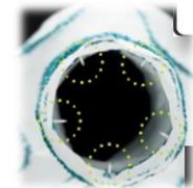
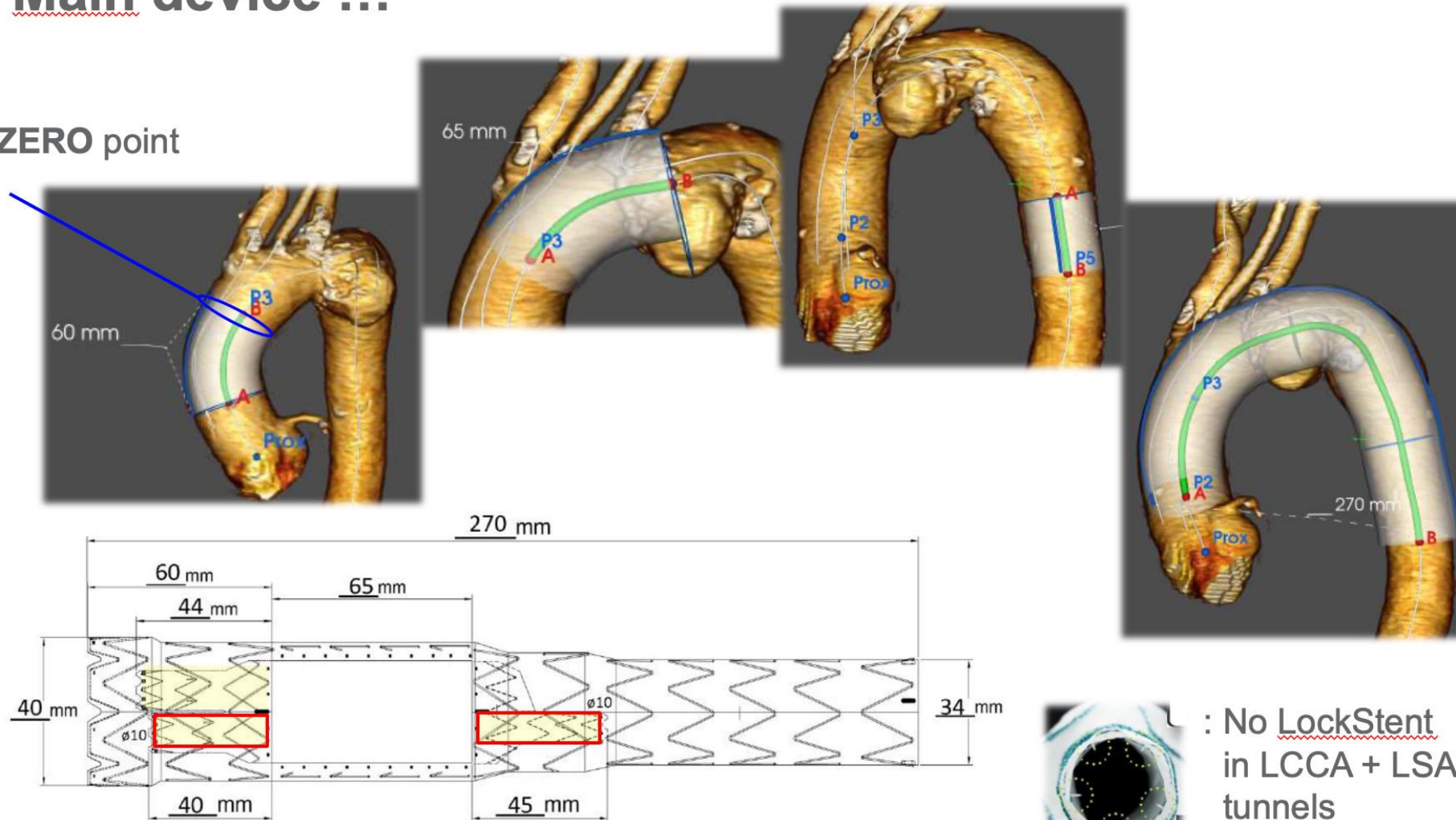
Main device ...

ZERO point



Main device ...

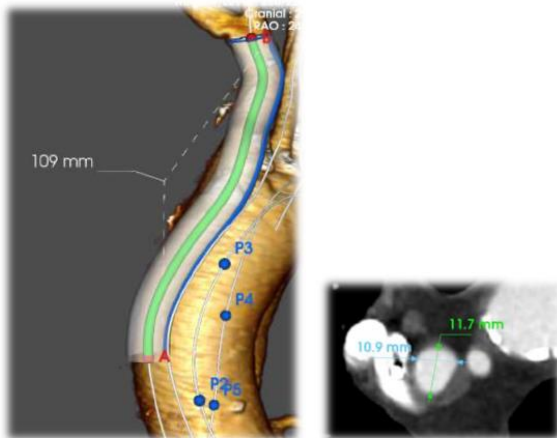
ZERO point



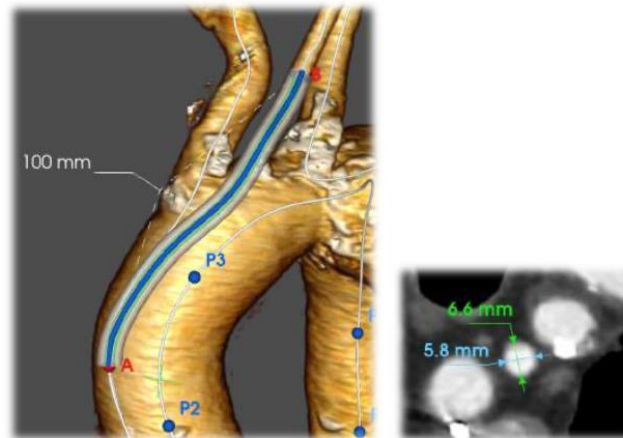
: No LockStent
in LCCA + LSA
tunnels

Branches ...

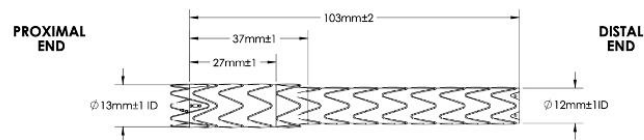
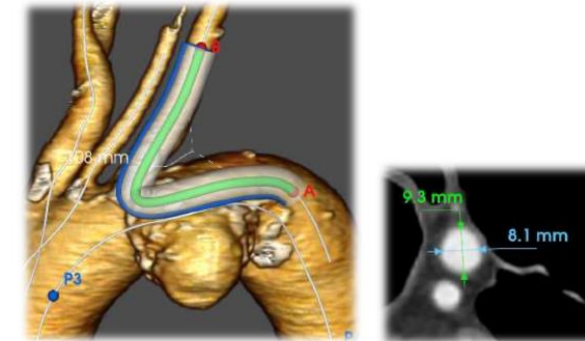
BCT



LCCA



LSA



TREO® 13x12x100



Viabahn BX 7x79
BX 7x59

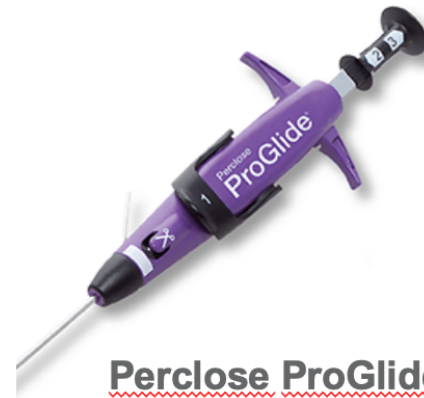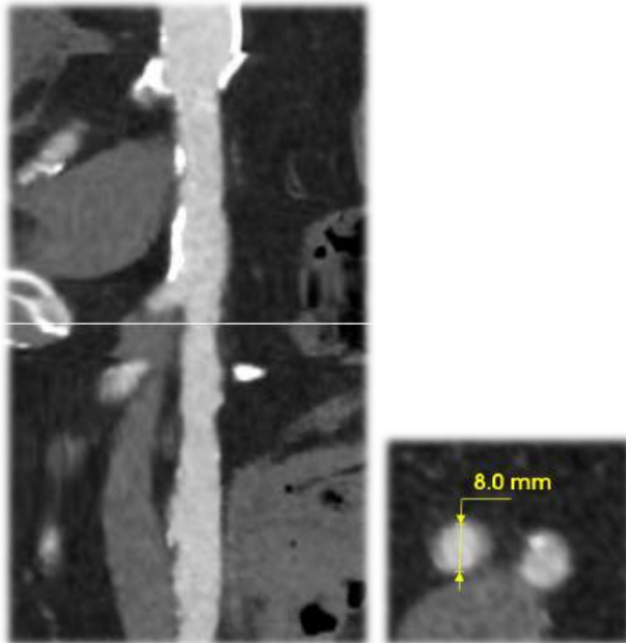


Viabahn SX 11x100



balloon 10mm

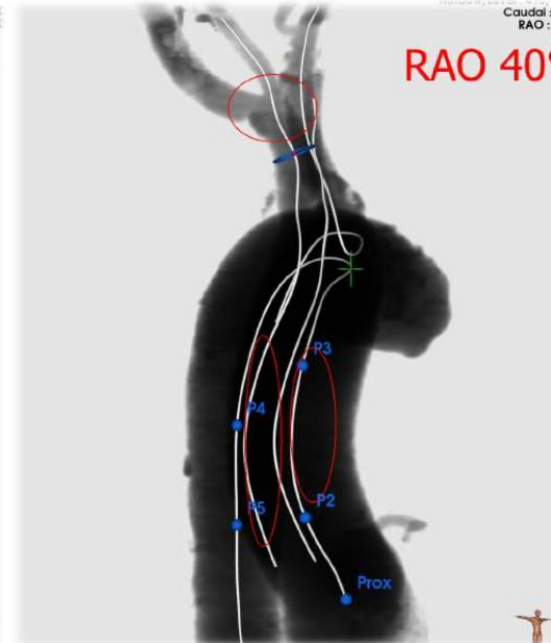
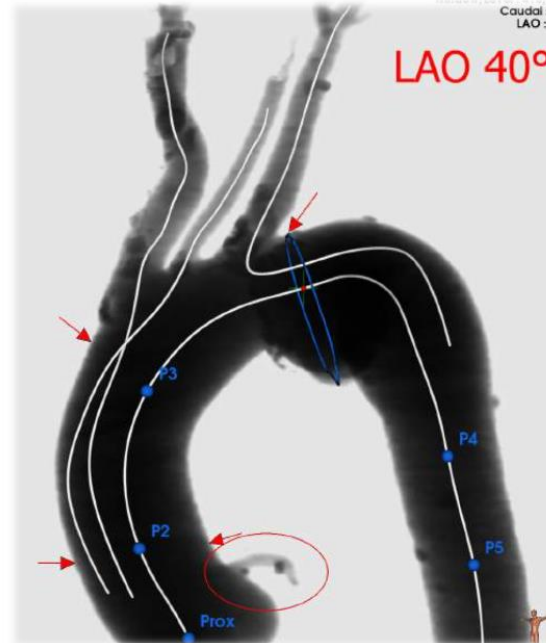
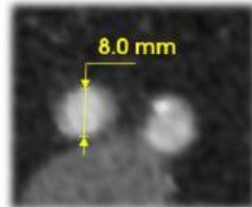
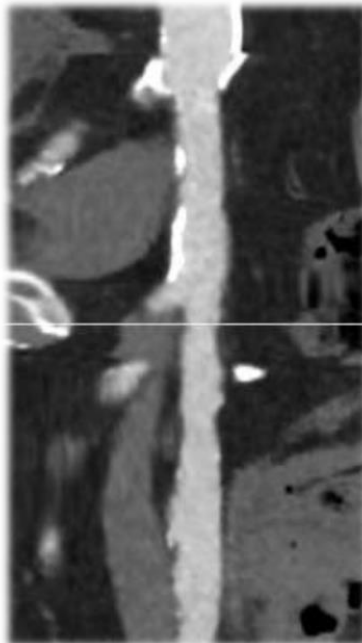
Arterial access ...



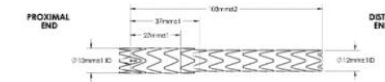
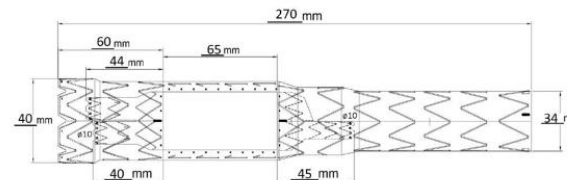
Perclose ProGlide (up to 26F)

25 Fr	8.33
26 Fr	8.66

Arterial access and C-arm position ...



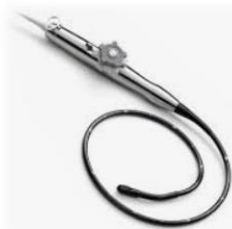25 Fr	8.33
26 Fr	8.66



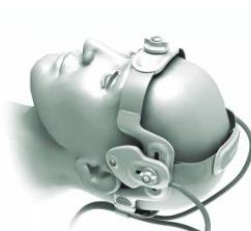Monitoring and equipment ...




double-curved
Lunderquist wire, 3m



TOE
for LV/ AoV and PE

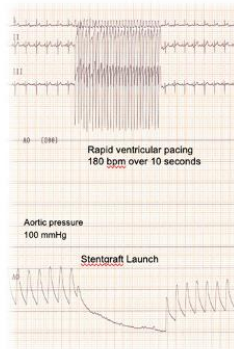


EEG and TCD
for neuromonitoring

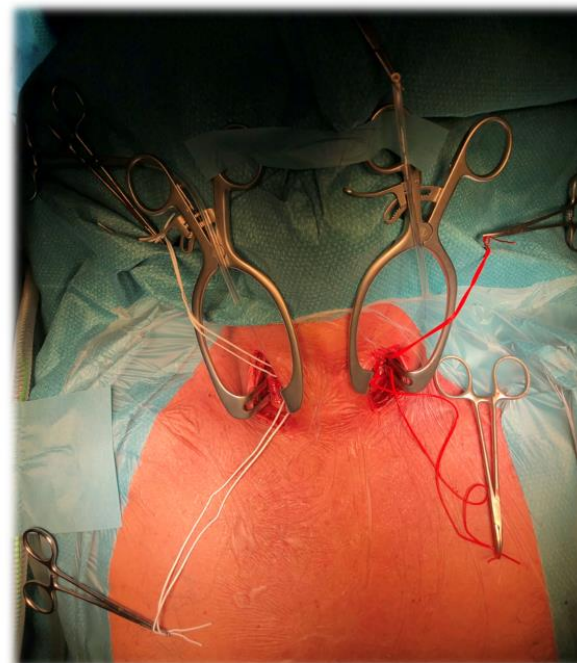


RR management
by IVC balloon occlusion

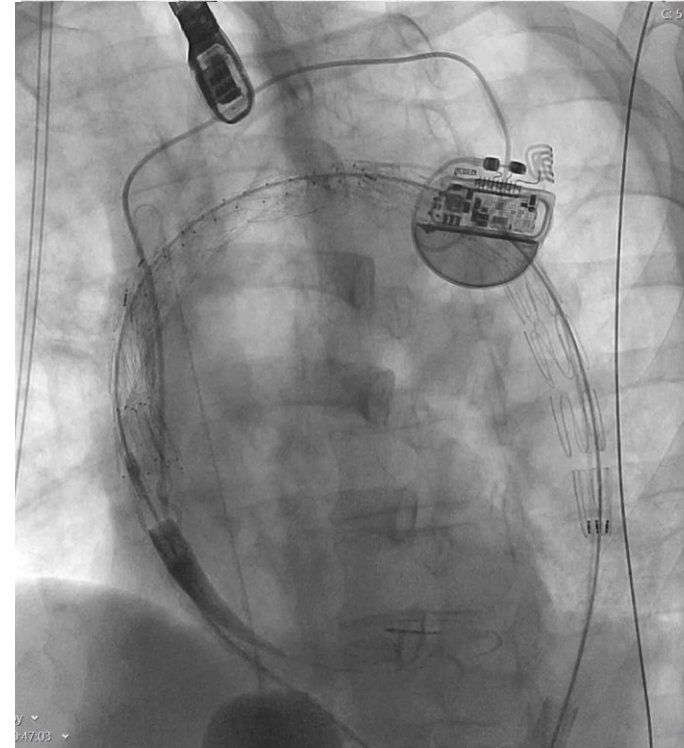
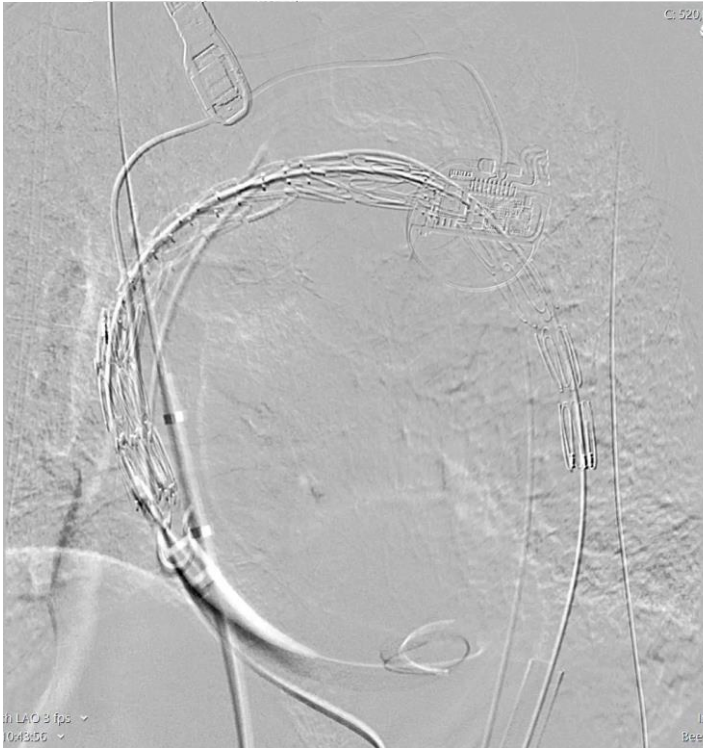Alternatively,
rapid RV-pacing :



Surgical exposure of
RCCA and LCCA


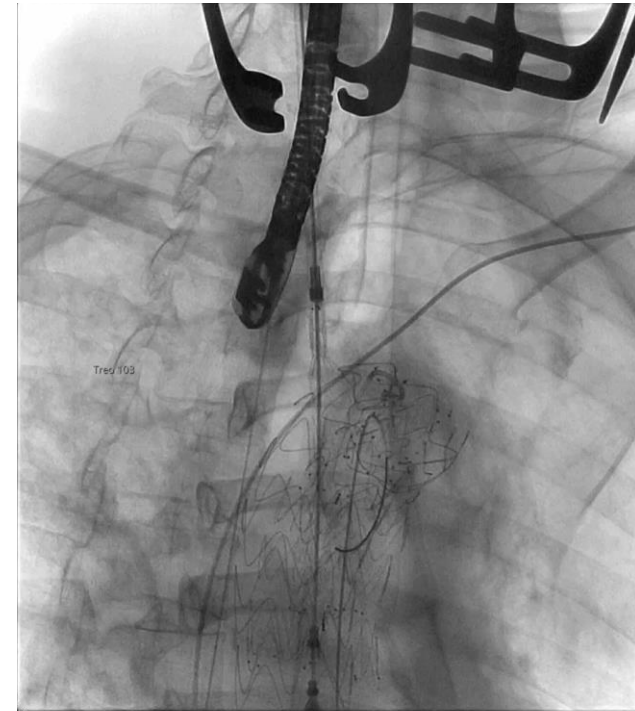
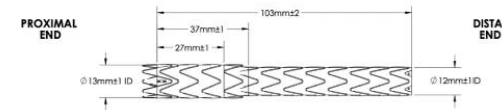
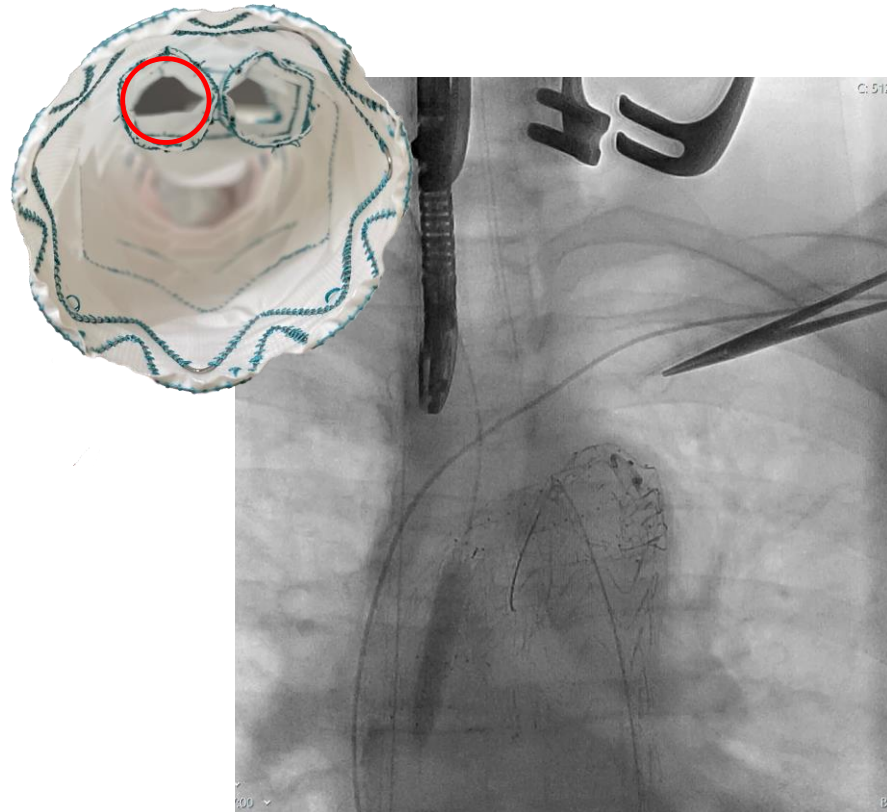


Main body ...



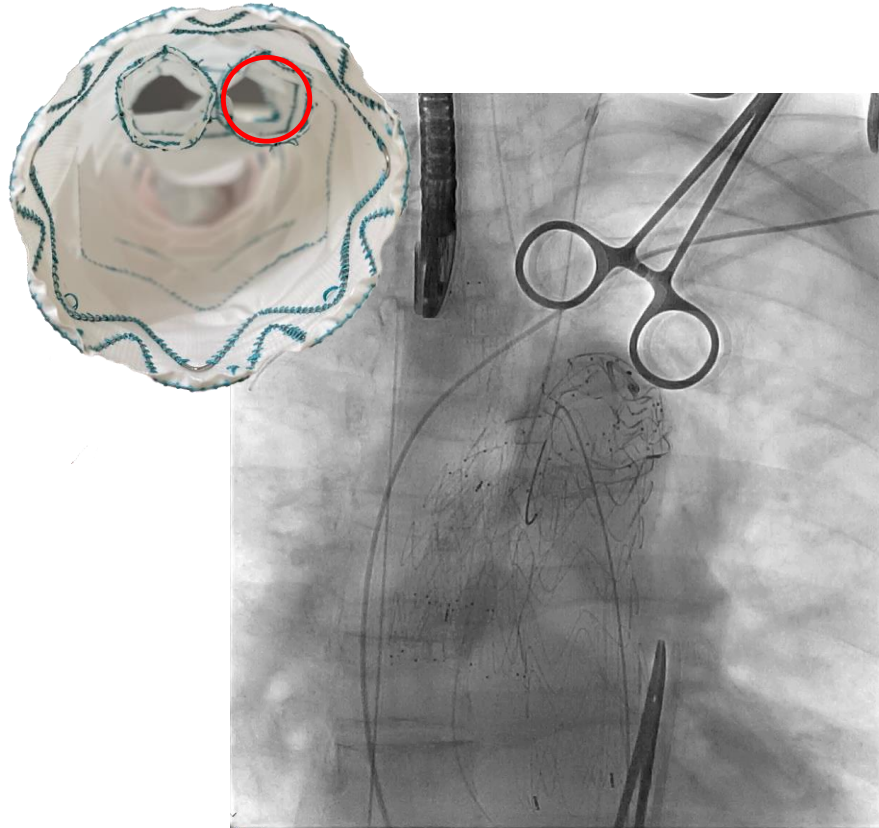
RR management
by IVC balloon occlusion

BCT tunnel and branch ...

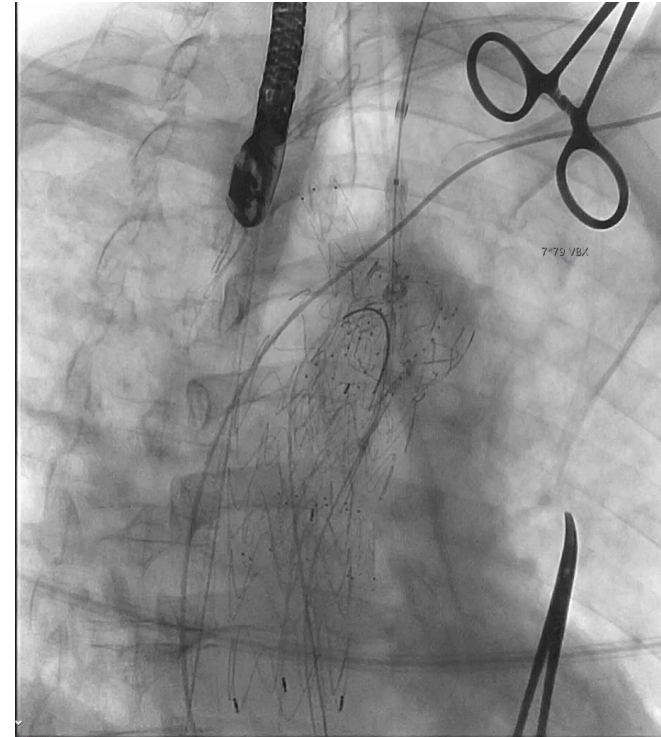

with LockStent

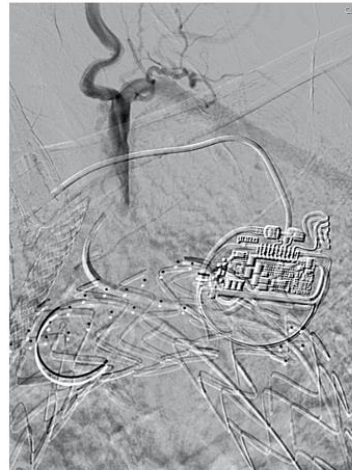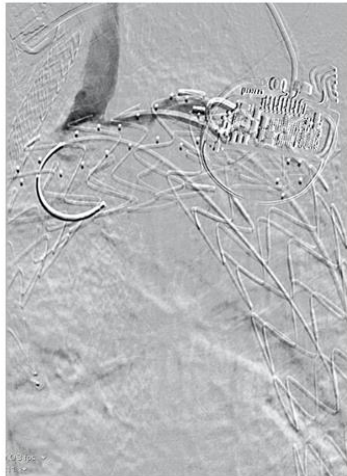
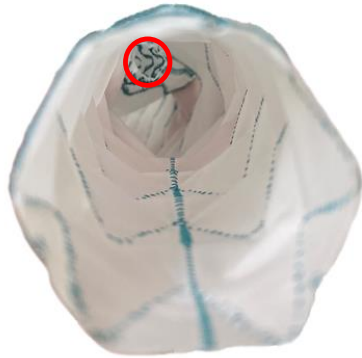
LCCA tunnel and branch ...



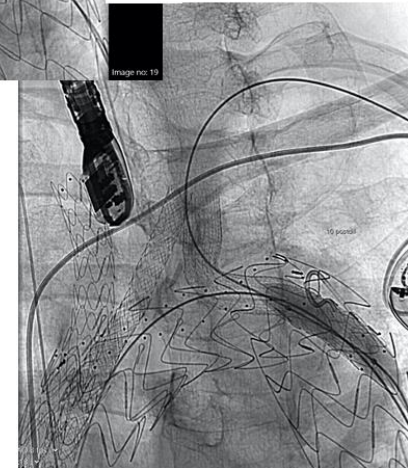
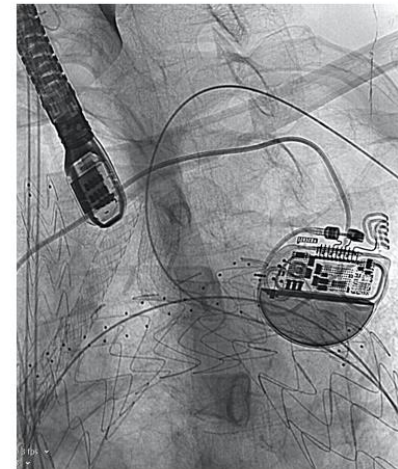
Viabahn BX 7x79
BX 7x59



LSA tunnel and branch ...

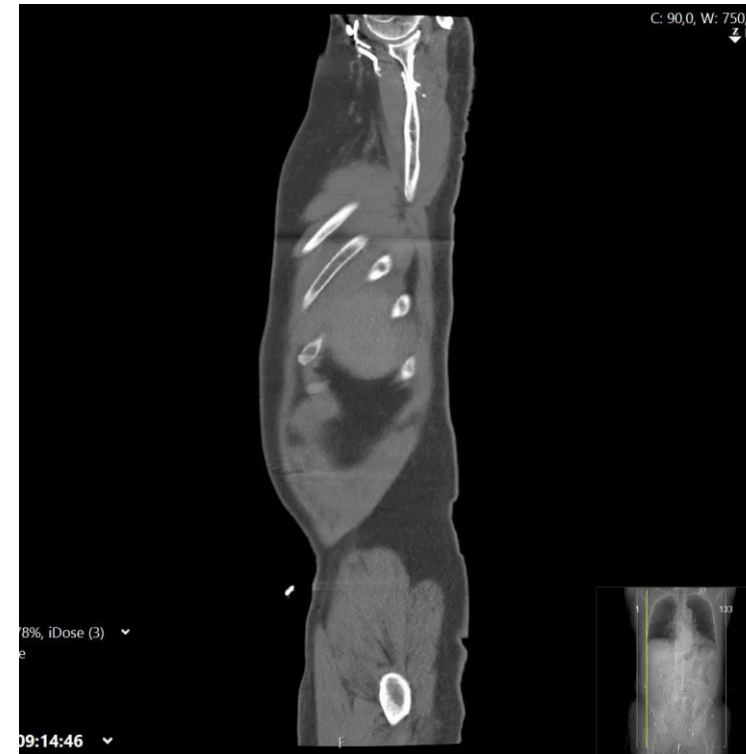
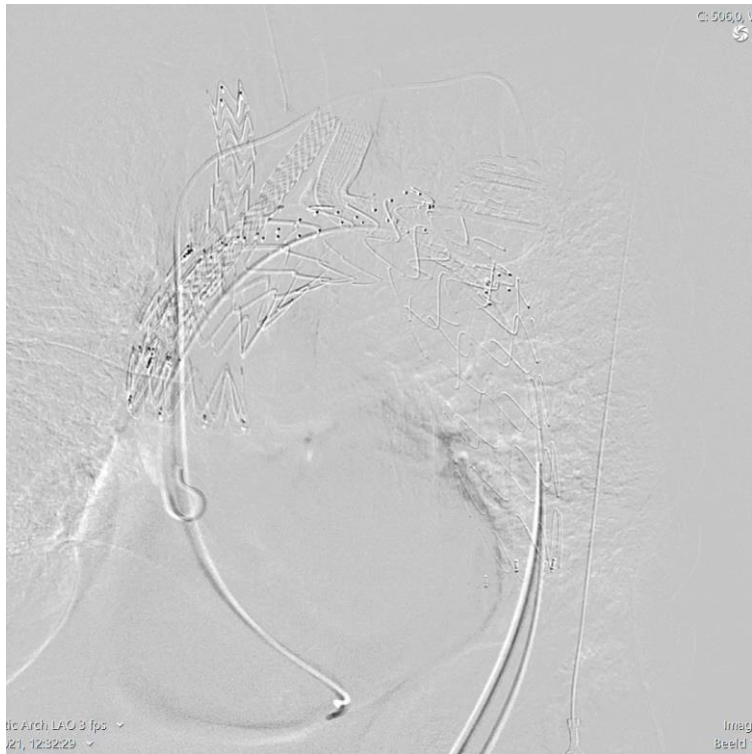
Viabahn SX 11x100

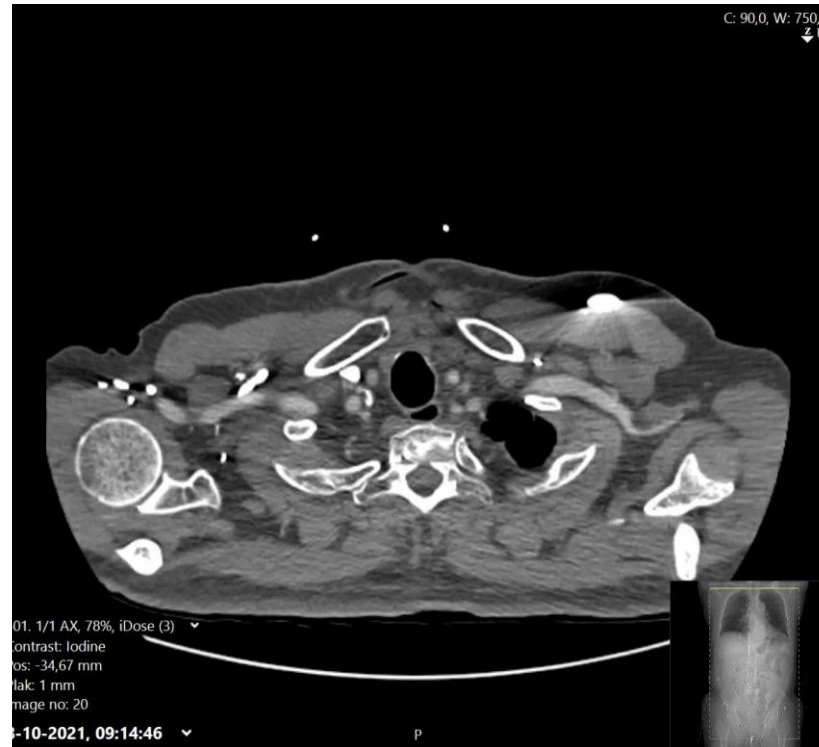
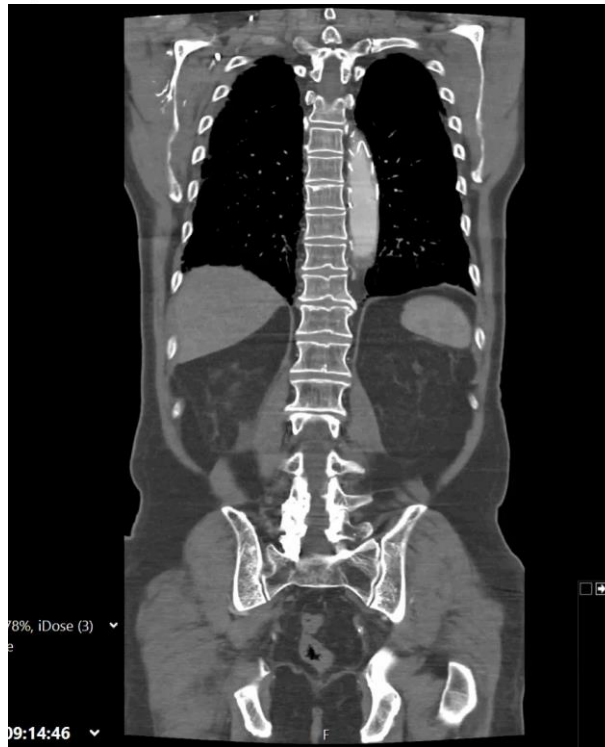
balloon 10mm

Completion angiography, and postop CT (at 1 week) ...



Postop CT (at 1 week) ...



M, 78-yr

... ↓↓ Pulmonary function

UNEVENTFUL RECOVERY
DISCHARGED HOME AT POD 4

