



Total Percutaneous Aortic Arch Repair


Stéphan Haulon, J. Mougin, T. Le Houérou, J. Bendavid, D. Fabre
J. Guihaire, R. Ramadan, P. Deleuze, S. Ghostine

Centre de l'Aorte, Hôpital Marie Lannelongue,
GHPSJ, Université Paris Saclay, France




GROUPE 
HOSPITALIER
 **PARIS**
SAINT  JOSEPH





Disclosures



- Research support, Consulting
 - Cook Medical, GE Healthcare, Bentley



Official Journal of the American Surgical Association and European Surgical Association



www.annalsurgery.com

Wolters Kluwer

Wolters Kluwer

ORIGINAL ARTICLE

Endovascular Treatment of Post Type A Chronic Aortic Arch Dissection With a Branched Endograft


Early Results From a Retrospective International Multicenter Study

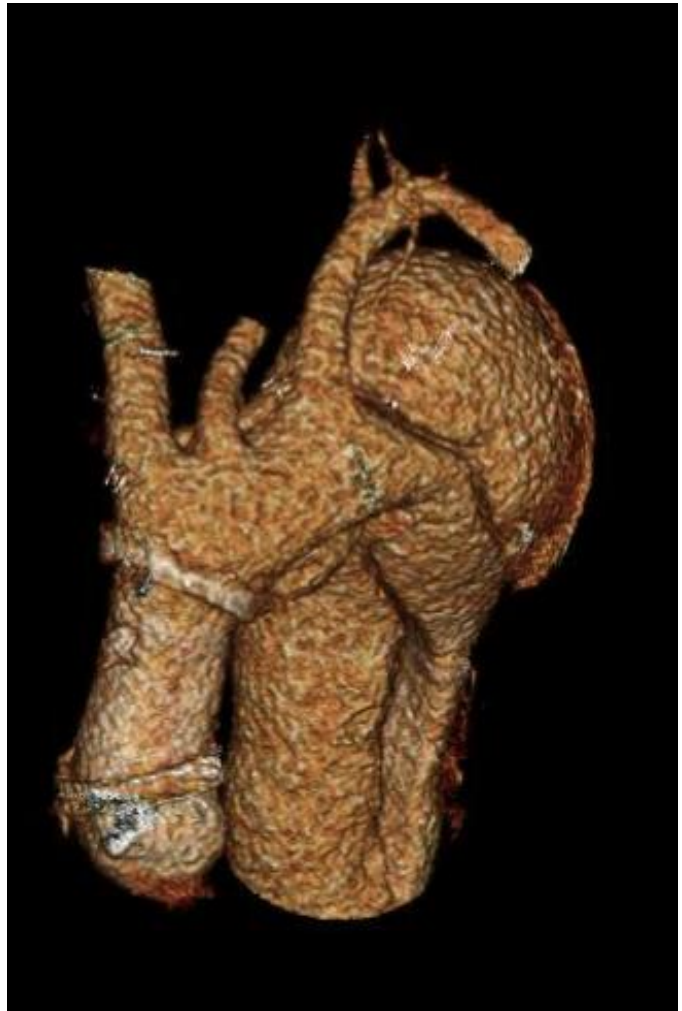
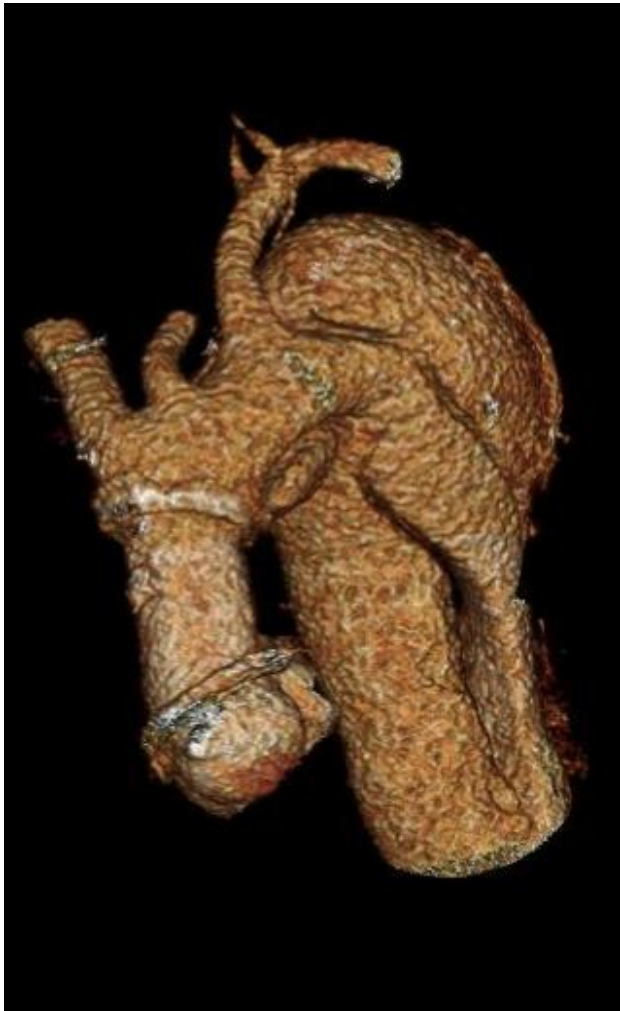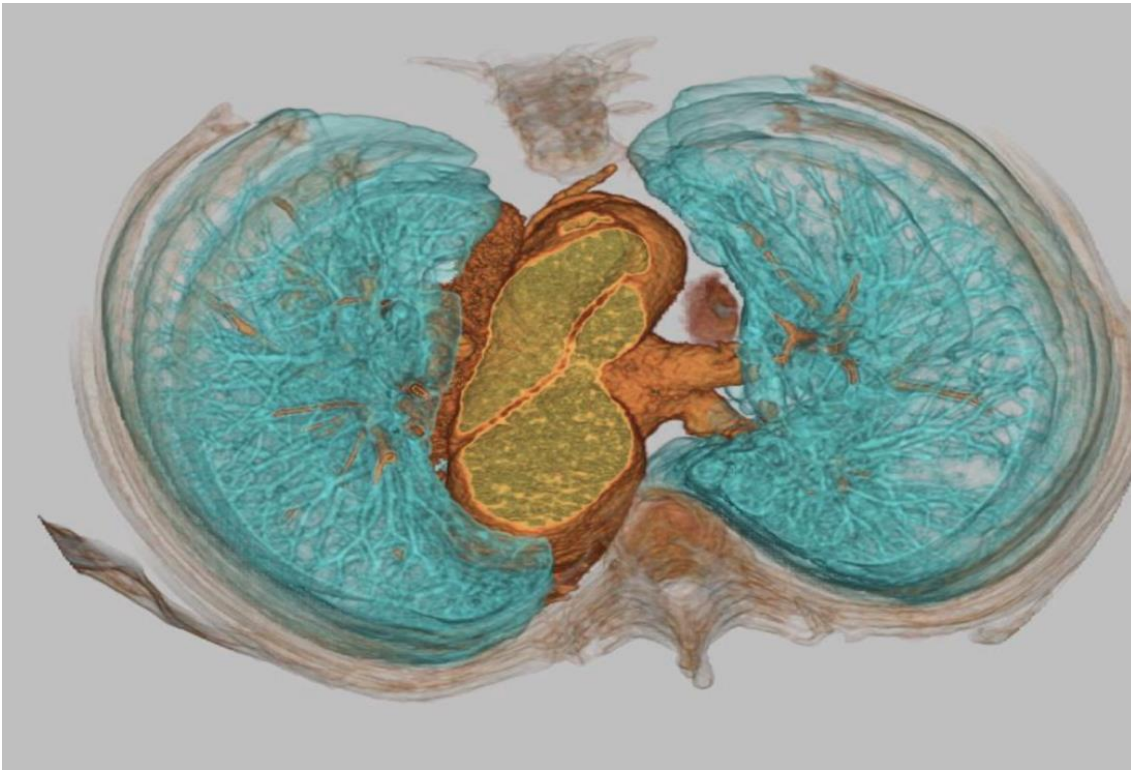
Dorian Verscheure, MD, Stéphan Haulon, MD, PhD,* Nikolaos Tsilimparis, MD, PhD,† Timothy Resch, MD, PhD,‡ Anders Wanhainen, MD, PhD,§ Kevin Mani, MD, PhD,§ Nuno Dias, MD, PhD,‡ Jonathan Sobocinski, MD, PhD,¶ Matthew Eagleton, MD,|| Marcelo Ferreira, MD,** Geert Willem Schurink, MD, PhD,†† Bijan Modarai, MD, PhD,‡‡ Said Abisi, MD,‡‡ Piotr Kasprzak, MD, PhD,§§ Donald Adam, MD,¶¶ Stephen Cheng, MD, PhD,|||| Blandine Maurel, MD, PhD,*** Tomasz Jakimowicz, MD,††† Amelia Claire Watkins, MD,‡‡‡ Björn Sonesson, MD, PhD,‡ Martin Claridge, MD,¶¶ Dominique Fabre, MD, PhD,* and Tilo Kölbel, MD, PhD†*




Inner Branched Arch Endografts following Ascending Open Repair

- 70 patients
- In-hospital combined mortality and stroke rate was 4% (n=3)
 - one minor stroke, one major stroke causing death, and one death following multi-organ failure.
- Technical success rate was 97%








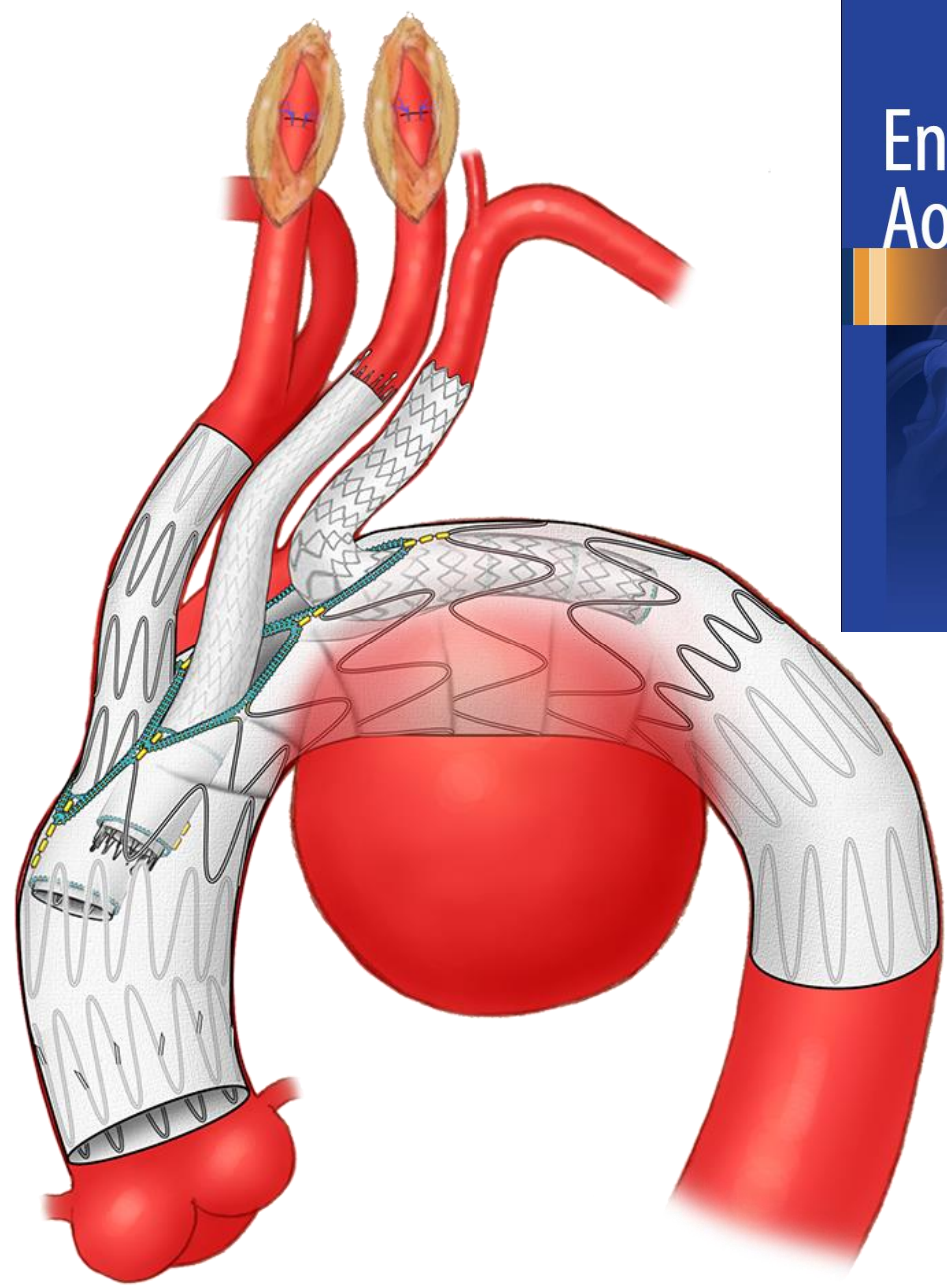
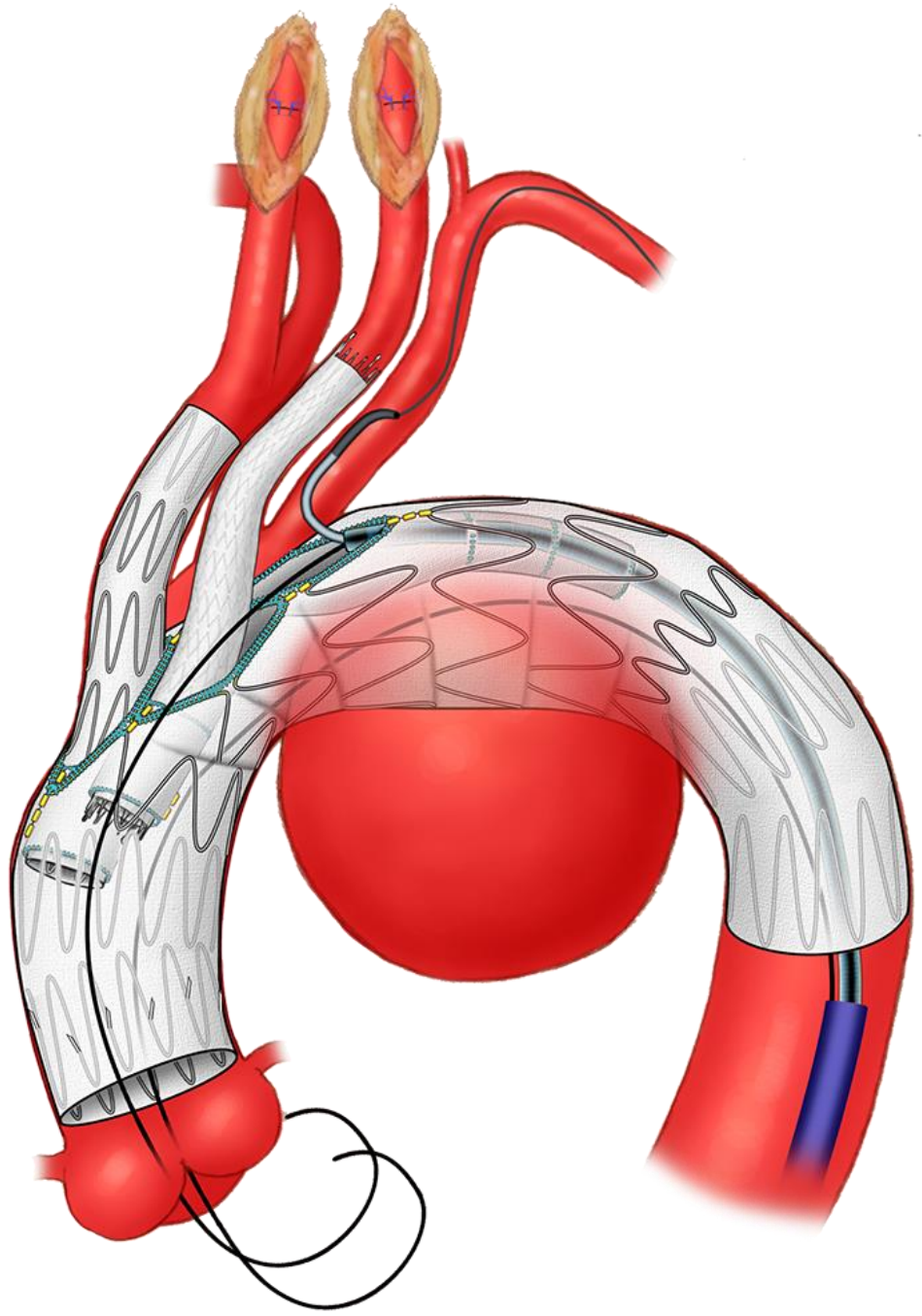
Gustavo S. Oderich
Editor

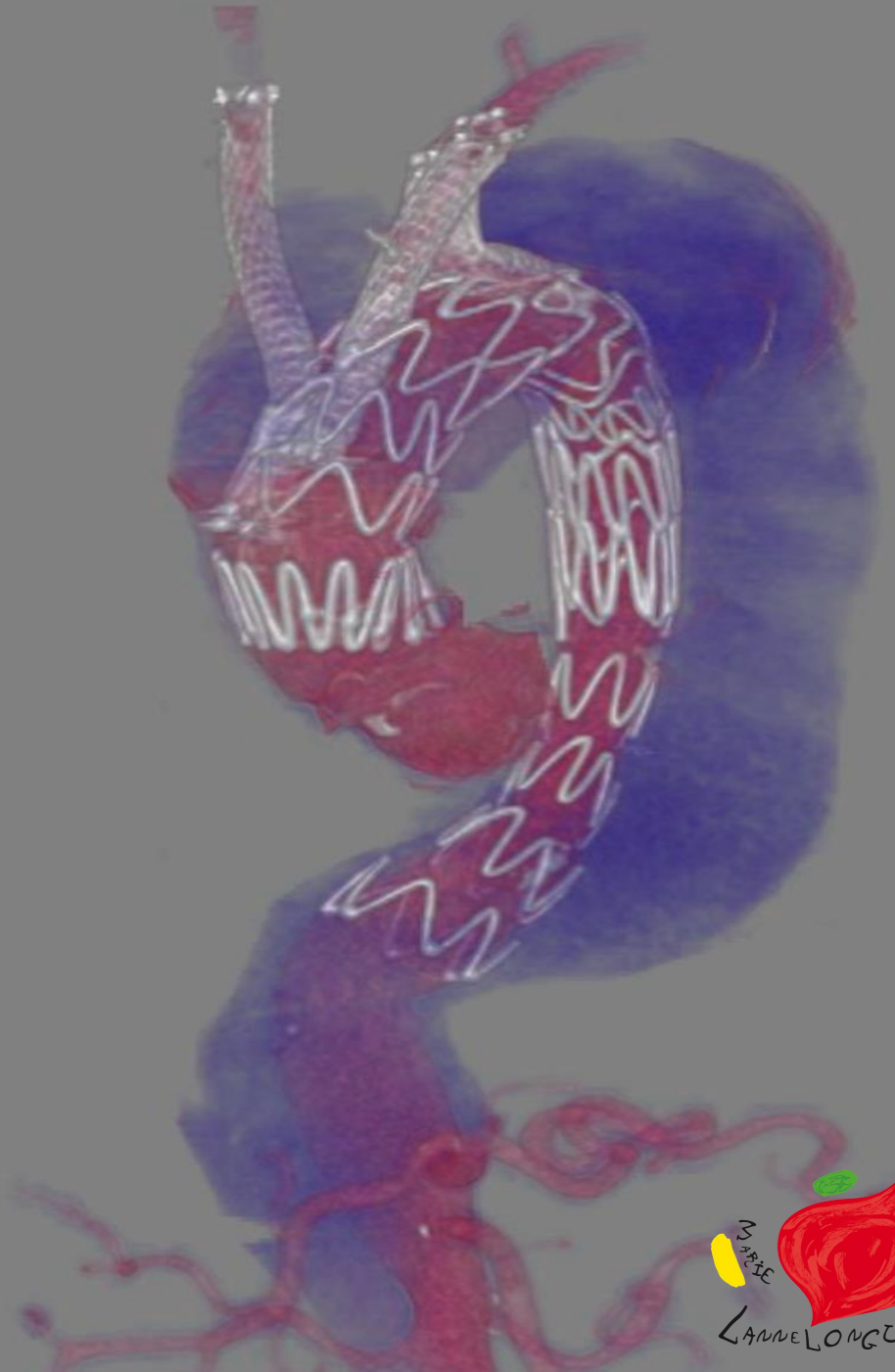
Endovascular Aortic Repair

Current Techniques with
Fenestrated, Branched
and Parallel Stent-Grafts

Illustrated by David Factor

Springer





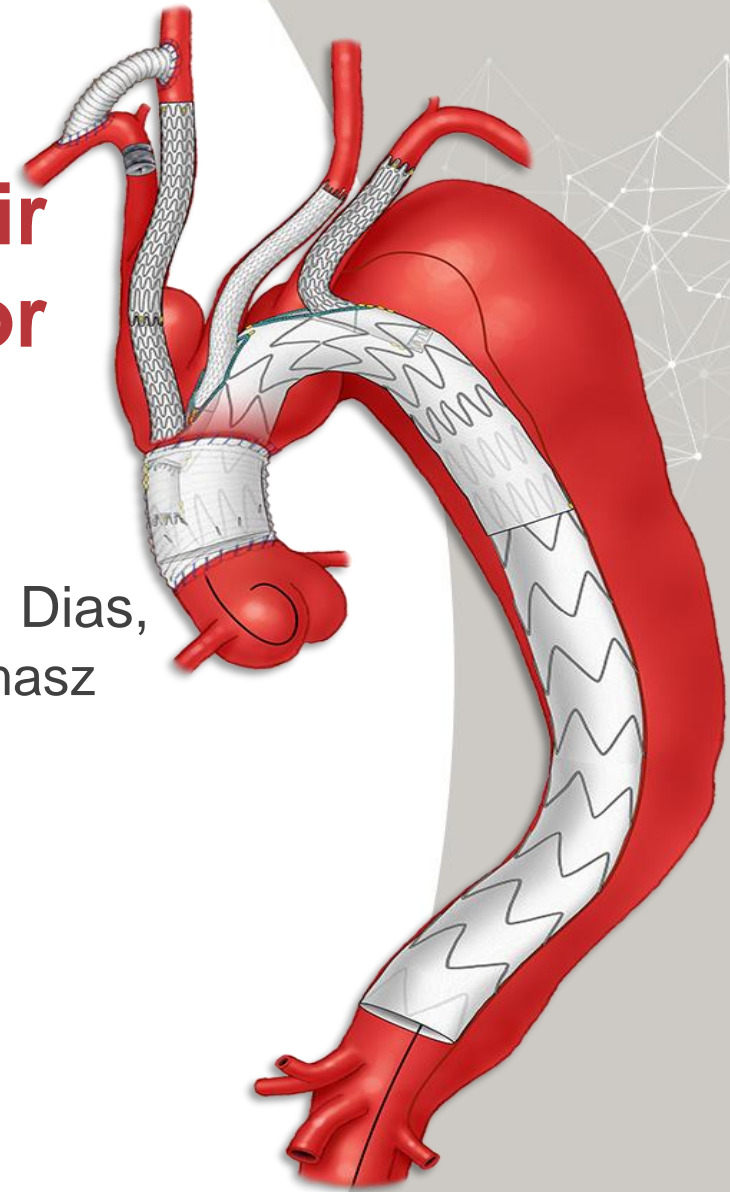
Multicenter global early feasibility study to evaluate total endovascular arch repair using three-vessel branch stent-grafts for aneurysm and dissections

Emanuel R. Tenorio, Gustavo S. Oderich, Tilo Kölbel, Nuno V. Dias, Mark A. Farber, Carlos H. Timaran, Nikolaos Tsilimparis, Thomasz Jakimowicz and Stéphan Haulon

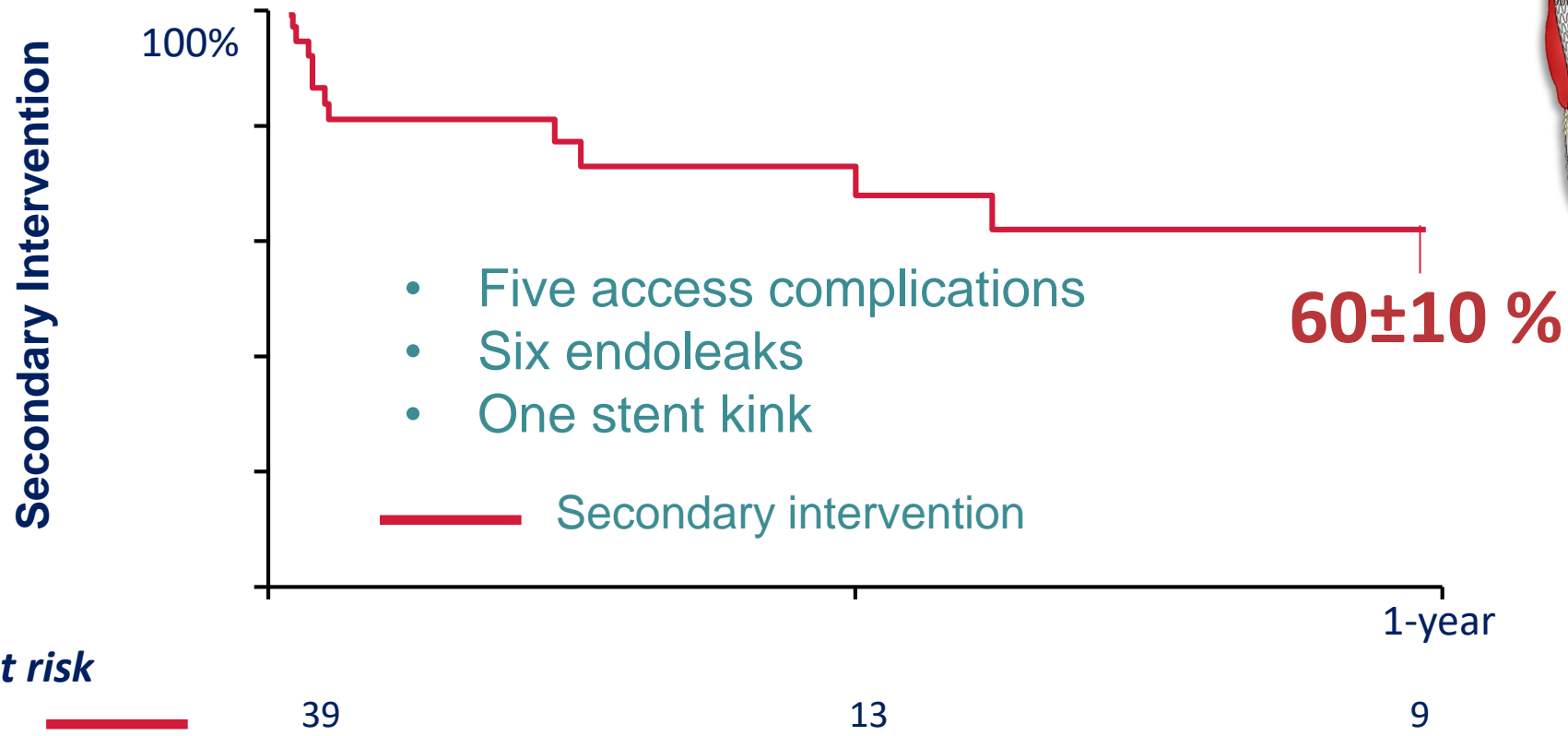
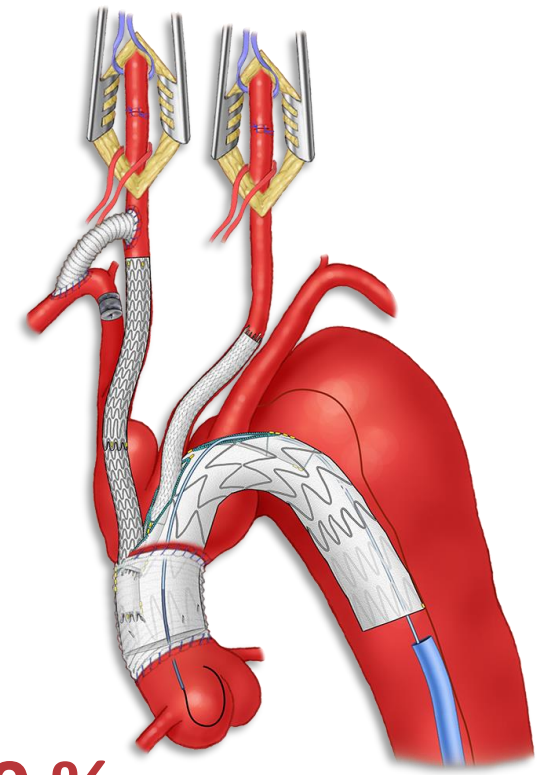
PRESENTED BY:

Emanuel R. Tenorio

Aortic Research Fellow / MD PhD
Mayo Clinic, Rochester, Minnesota




Secondary intervention


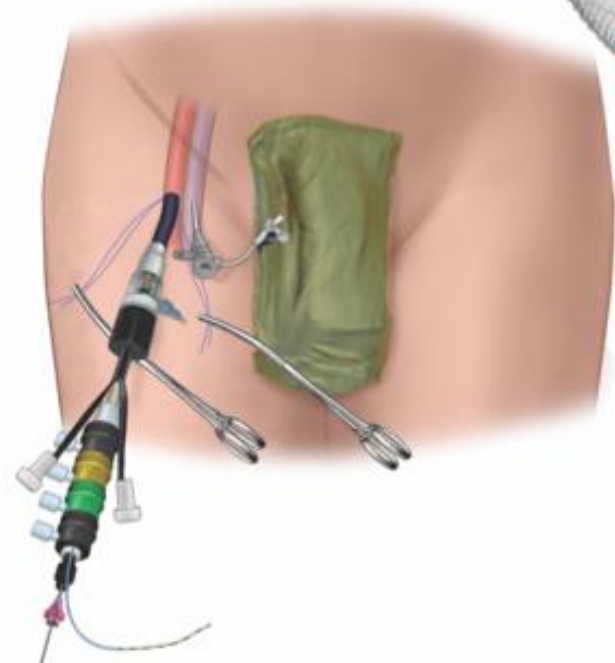
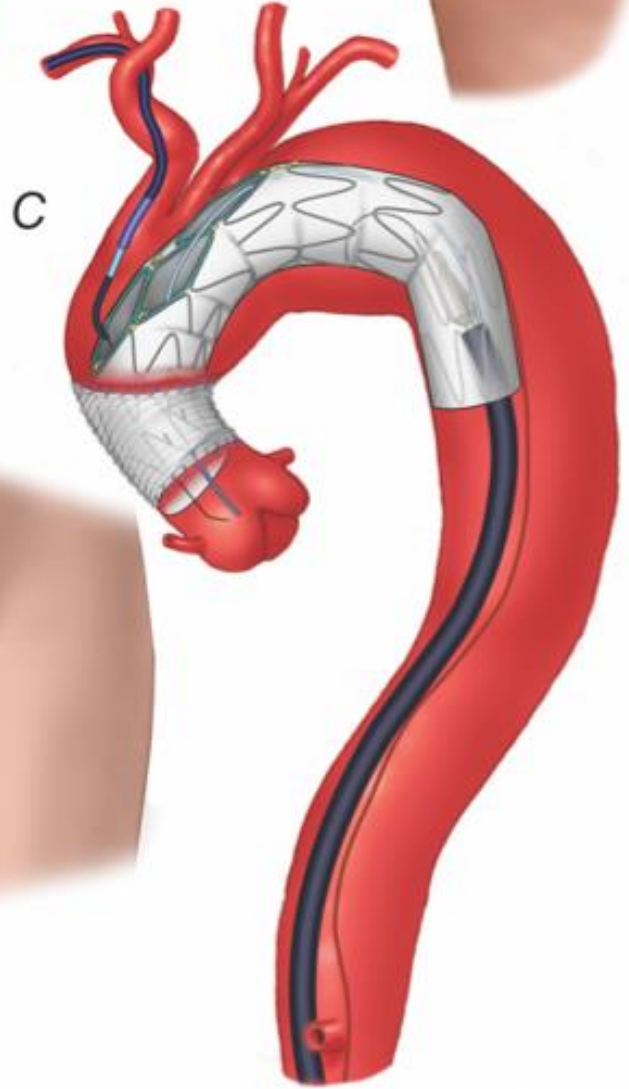
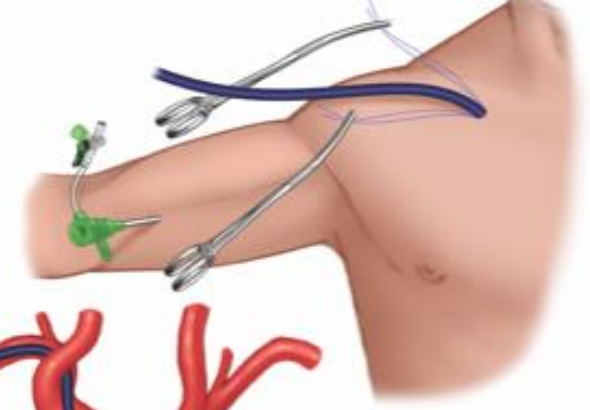
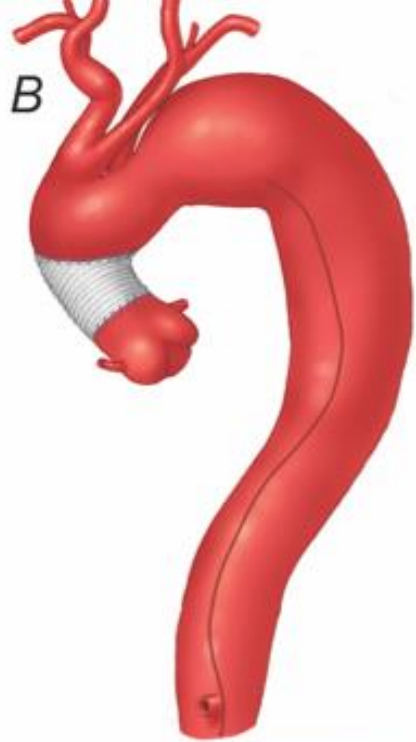



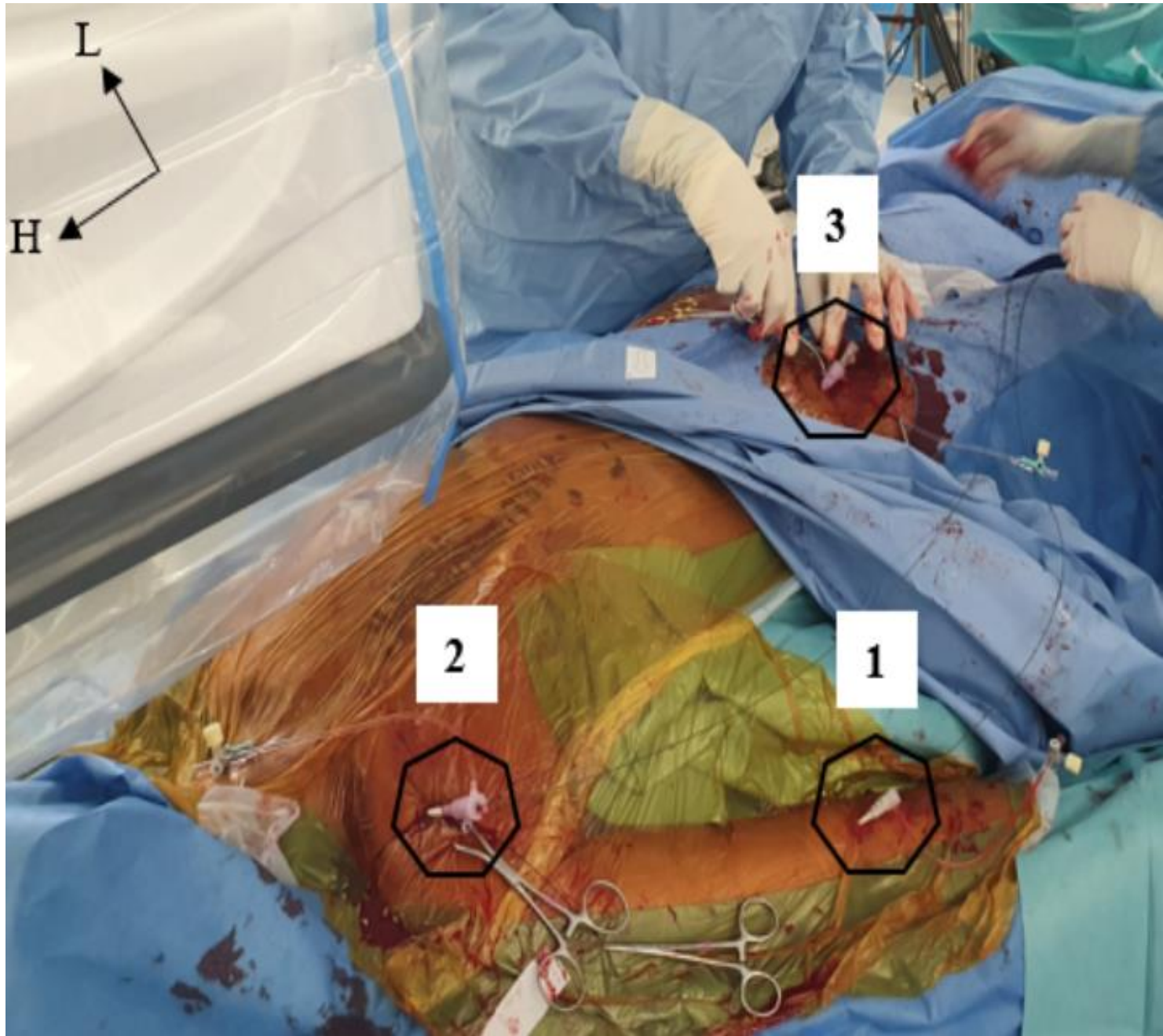
"First in man" total percutaneous aortic arch repair with 3-inner-branch Endografts

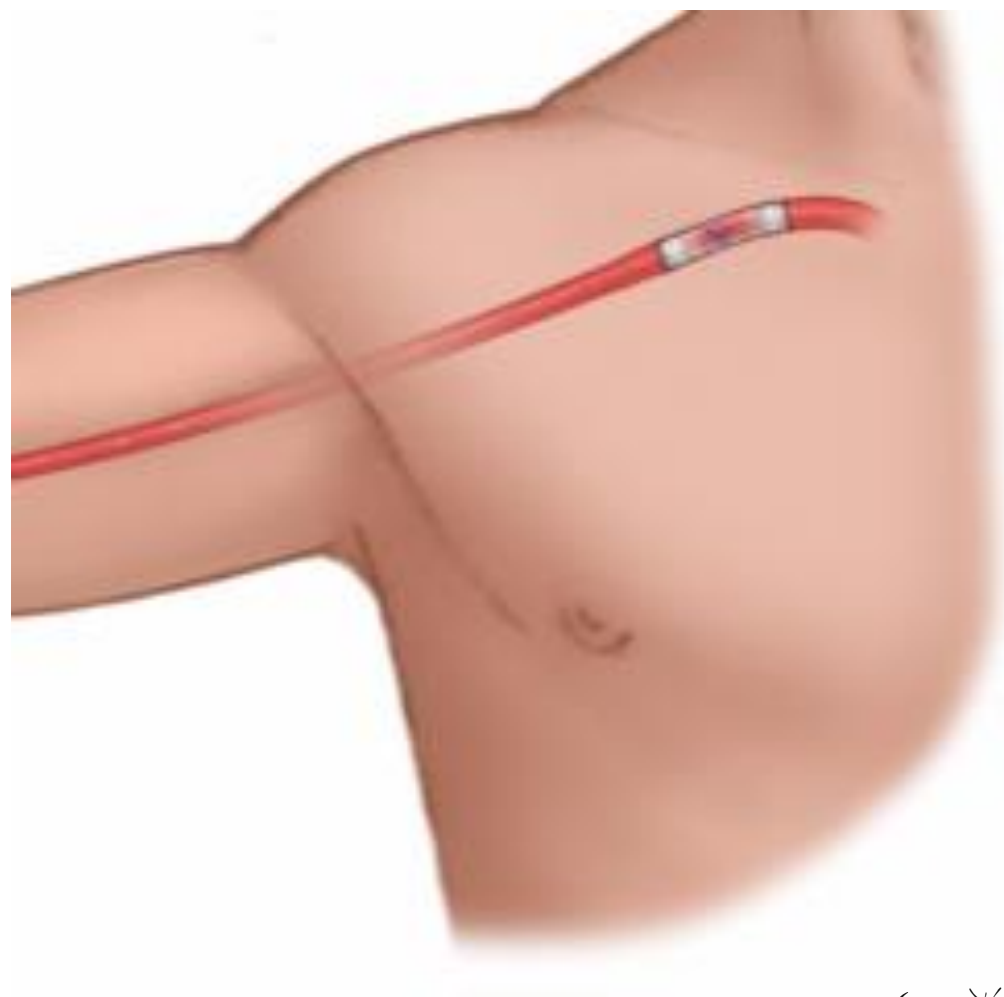
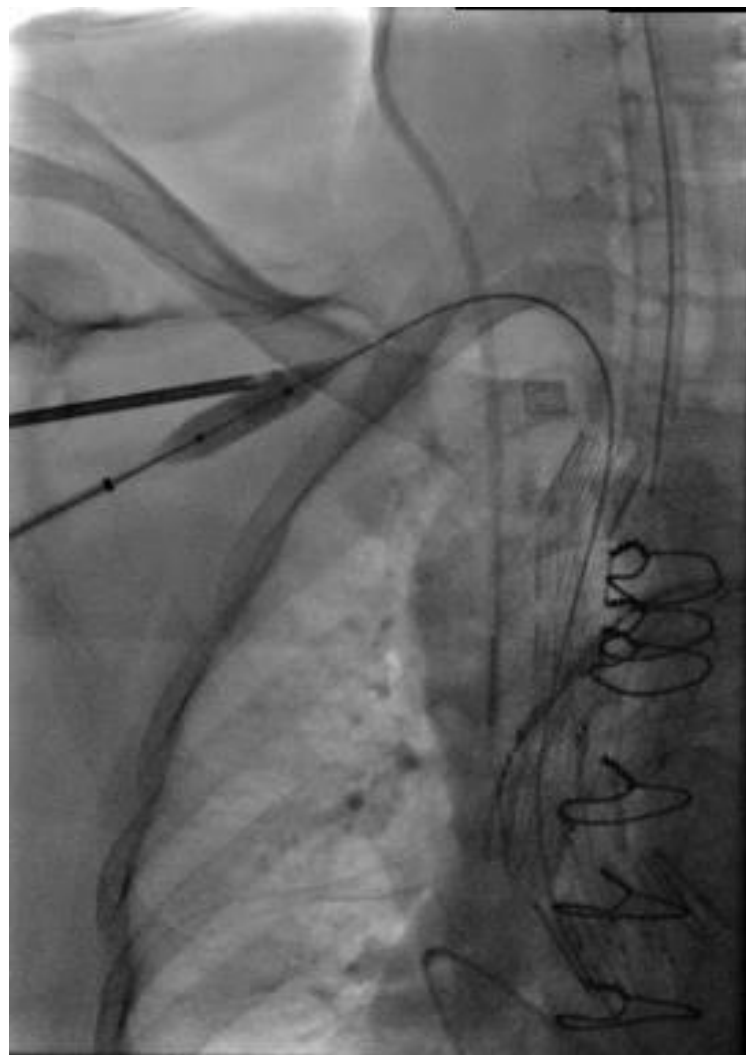
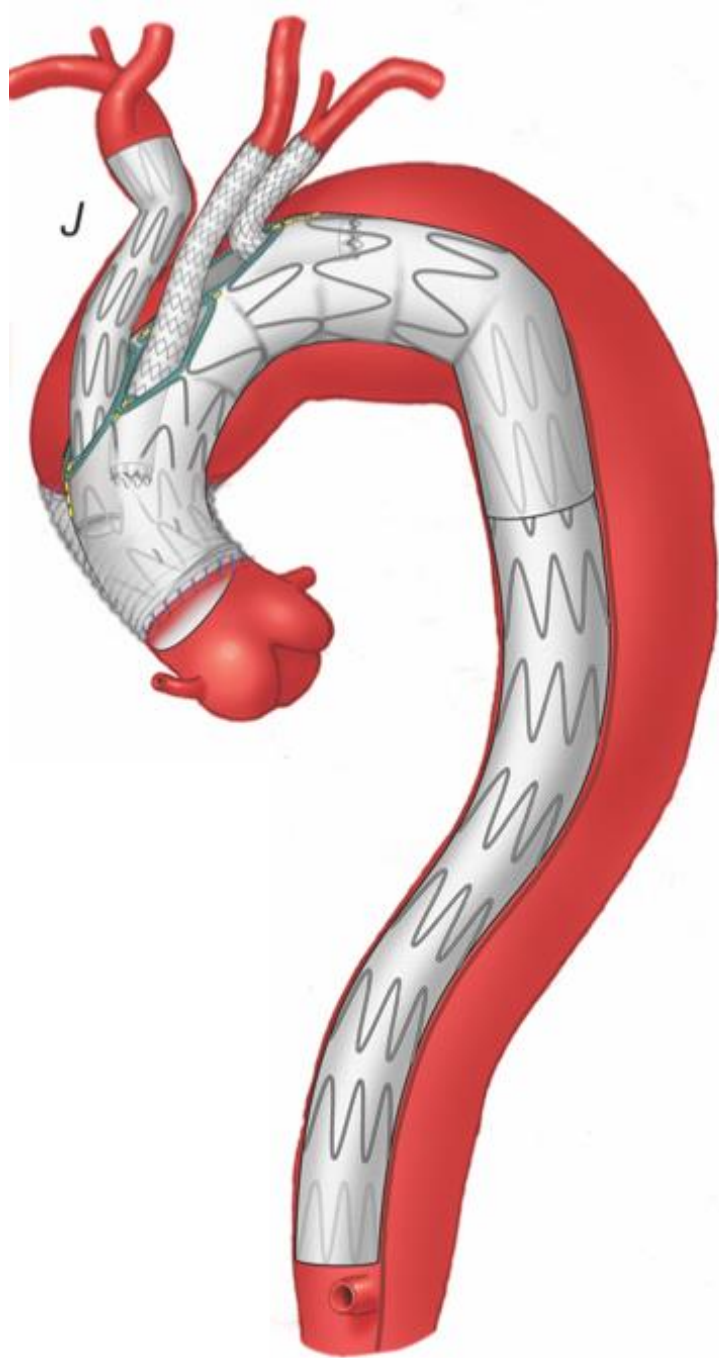
J Mougin, R Azogui, J Guihaire, MR Tyrrell, G Oderich, D Fabre, Stephan Haulon





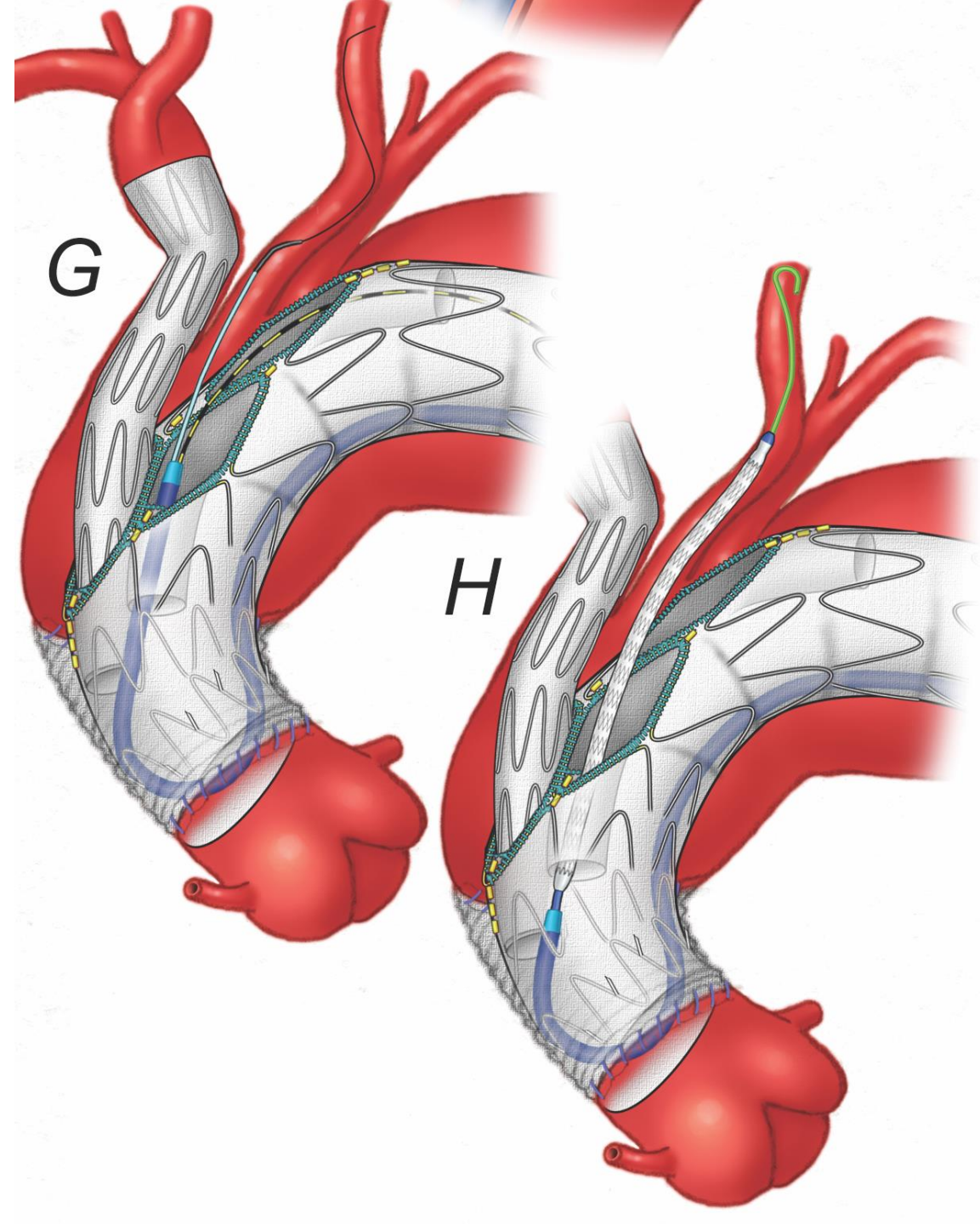
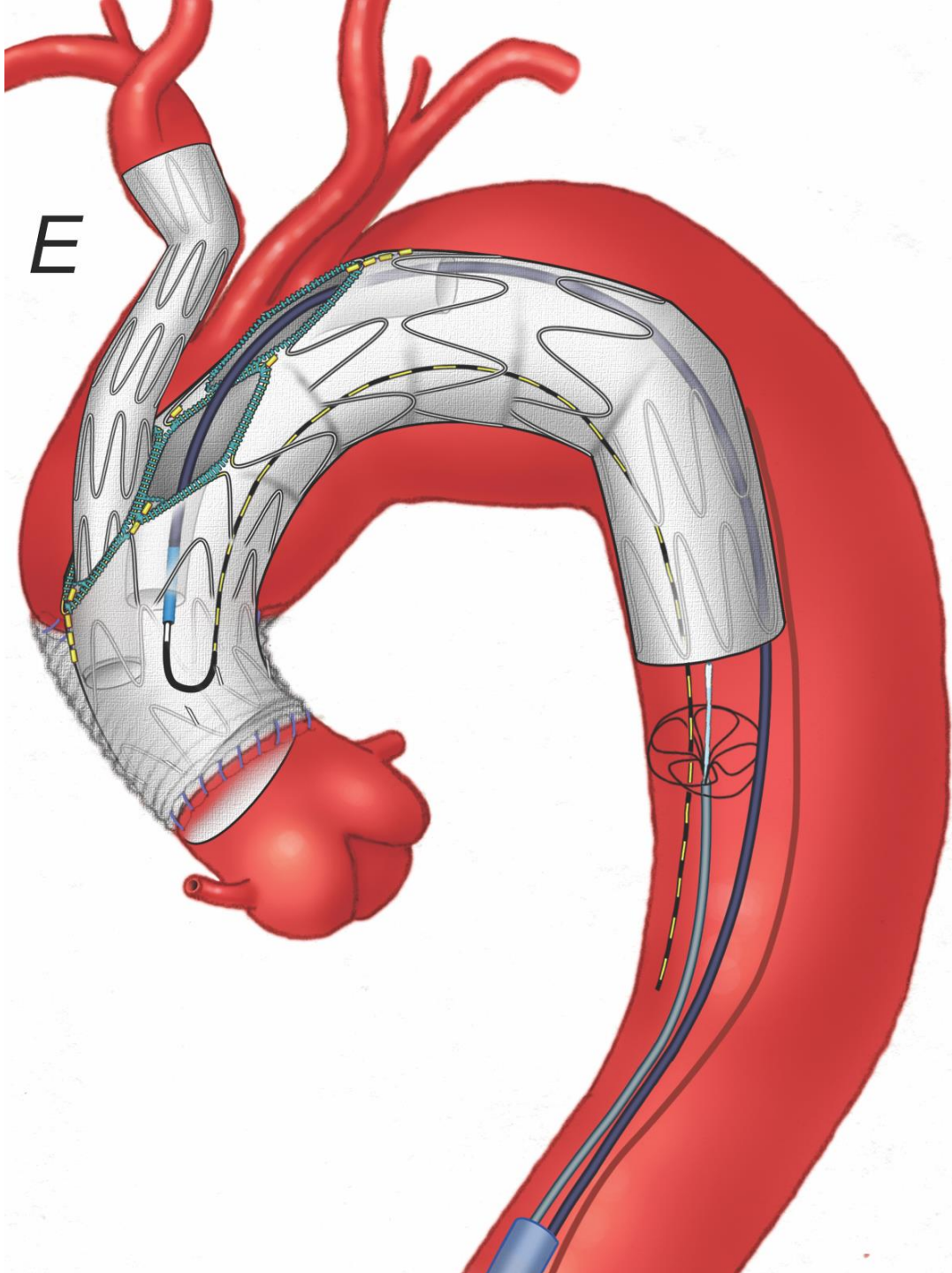
GROUPE 
HOSPITALIER
 **PARIS**
SAINT  JOSEPH

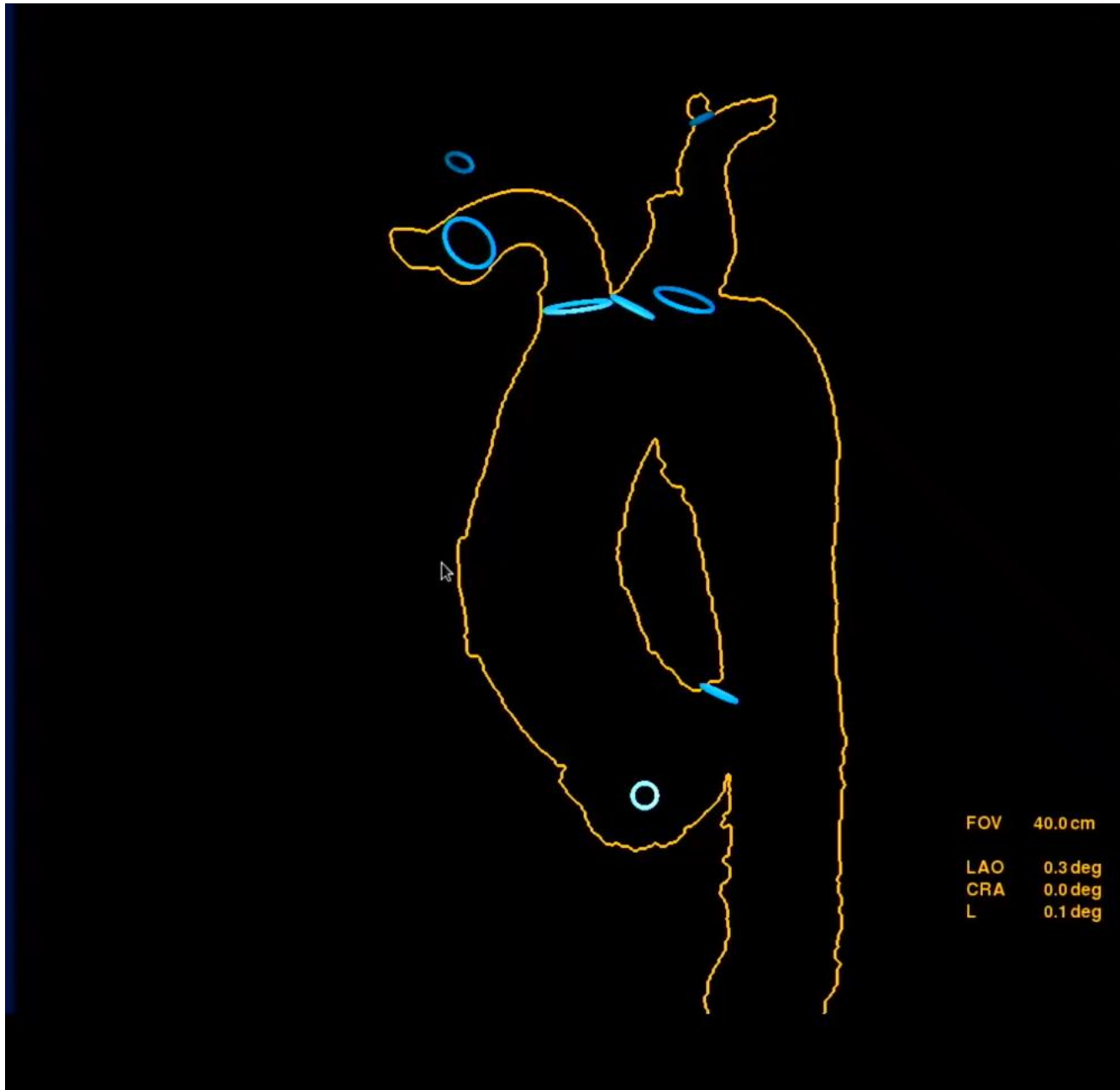



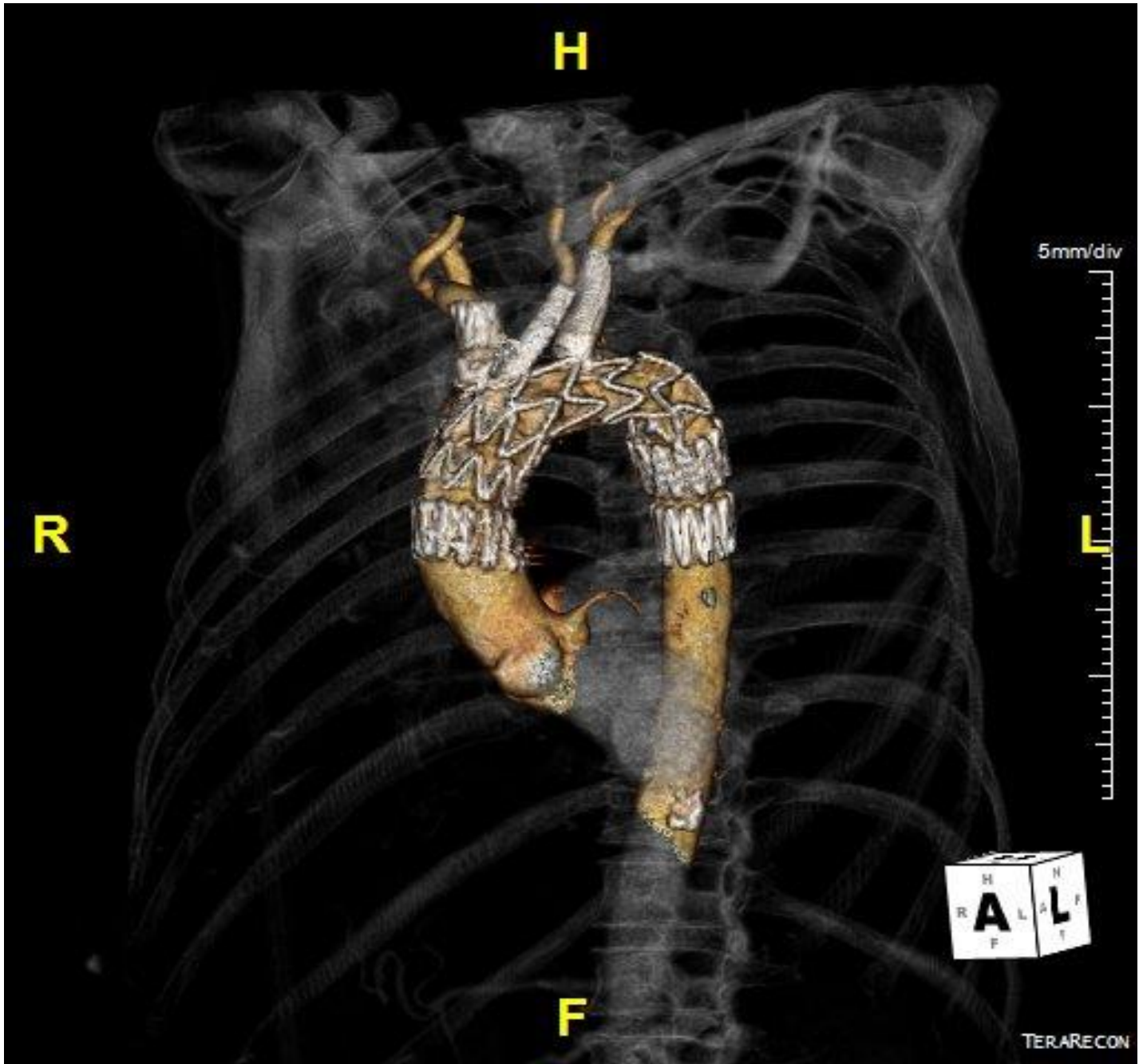













CONCERNS

- Carotid clamping (filters)
- Access from axillary (Stiff wire in LV)



BENEFITS

- Avoid bilateral carotid cutdowns
- No neck hematoma/swelling (ACT>350s)
- Swift workflow
- FUTURE!

